

Intensive Care Unit Management of Patients with Severe Pulmonary Hypertension and Right Heart Failure

Marius M. Hoeper¹ and John Granton^{2,3}

¹Department of Respiratory Medicine, Hannover Medical School, Hannover Germany; and ²Faculty of Medicine and ³Interdepartmental Division of Critical Care, University of Toronto, Toronto, Ontario, Canada

Despite advances in medical therapies, pulmonary arterial hypertension (PAH) continues to cause significant morbidity and mortality. Although the right ventricle (RV) can adapt to an increase in afterload, progression of the pulmonary vasculopathy that characterizes PAH causes many patients to develop progressive right ventricular failure. Furthermore, acute right ventricular decompensation may develop from disorders that lead to either an acute increase in cardiac demand, such as sepsis, or to an increase in ventricular afterload, including interruptions in medical therapy, arrhythmia, or pulmonary embolism. The poor reserve of the right ventricle, RV ischemia, and adverse right ventricular influence on left ventricular filling may lead to a global reduction in oxygen delivery and multiorgan failure. There is a paucity of data to guide clinicians caring for acute right heart failure in PAH. Treatment recommendations are frequently based on animal models of acute right heart failure or case series in humans with other causes of pulmonary hypertension. Successful treatment often requires that invasive hemodynamics be used to monitor the effect of strategies that are based primarily on biological plausibility. Herein we have developed an approach based on the current understanding of RV failure in PAH and have attempted to develop a treatment paradigm based on physiological principles and available evidence.

Keywords: pulmonary hypertension; right ventricular failure; intensive care; extracorporeal life support

Right ventricular (RV) failure is the most common cause of death in patients with pulmonary hypertension, and RV function is the major determinant of morbidity and mortality in this patient population (1). There is, however, no universally accepted definition of RV failure. Clinically, RV failure is characterized by a reduced cardiac output (i.e., cardiac index < 2.5 L/min/m²) and an elevation in RV filling pressure (i.e., right atrial pressure > 8 mm Hg).

Right ventricular failure is a common complication of pulmonary hypertension (PH). RV failure can also result from other diseases such as myocarditis, cardiomyopathy, or myocardial infarction, but these conditions are not covered in the present overview. Although any form of PH can result in RV dysfunction, the full picture of RV failure with low cardiac output and elevated RV filling pressures is typically seen in patients with pulmonary arterial hypertension (PAH) or chronic thromboembolic pulmonary hypertension (CTEPH), that is, groups 1 and 4 according to the current classification (Table 1) (2, 3). Patients with PH due

to left heart disease (Table 1, group 2) or due to lung disease and/or hypoxia (Table 1, group 3) may also present with clinical signs and symptoms of RV failure, especially with fluid retention associated with RV diastolic dysfunction and elevated right-sided filling pressures. Low cardiac output RV failure, however, is less common in these patient populations. On occasion, patients may present with clinical signs of RV failure in a state of markedly elevated rather than reduced cardiac output. This so-called *high-output failure* is typically seen in patients with large arteriovenous malformations (e.g., in patients with hereditary hemorrhagic telangiectasia) (4), or in patients with chronic hemolytic anemia (e.g., sickle cell disease) (5), and is not addressed further in this review.

In the past it was not unusual to see patients being admitted to the intensive care unit (ICU) with RV failure due to undiagnosed and untreated PAH. Fortunately, with increased awareness of the condition, this scenario has become increasingly rare. Today, the majority of patients with PH and RV failure admitted to the ICU have exhausted their medical treatment options, which renders their management particularly challenging and, at times, frustrating. Patients with overt RV failure have never been included in randomized, controlled clinical trials and few articles have specifically addressed this patient population. Contemporary guidelines make no specific recommendations regarding the ICU management of patients with RV failure (6–9). To the best of our knowledge, only a few authoritative review articles on this subject have been published (10–13) and an update seems timely given the advances in this area. A systematic review of the treatment of patients with pulmonary hypertension was completed by Price and coworkers (11). As emphasized in that report, many of the treatments have not been systematically evaluated and most of the recommendations relate to biological plausibility and extrapolation from acute animal models of PH.

In this article we review the ICU management of patients with PH and RV failure. We are not going to address acute pulmonary embolism and postoperative right heart failure after cardiac surgery, and will not cover the specific considerations regarding pediatric patients with pulmonary vascular disease. Our recommendations are based on physiological principles, published reports as well as personal experience.

PATHOPHYSIOLOGY OF RIGHT VENTRICULAR FAILURE

The RV is embryologically, morphologically, and functionally distinct from the left ventricle (LV) (14–17). After birth it assumes the adult phenotype of a relatively thin-walled, crescent-shaped structure that is adapted to eject into the pulmonary circulation; a circuit characterized by low resistance, high compliance, and low impedance (15). The RV and LV are interrelated by the shared interventricular septum. The relatedness is also conferred by the surrounding pericardium, which ensures a consistent beat-to-beat intracardiac volume (18, 19). RV–LV interaction, under

(Received in original form April 13, 2011; accepted in final form June 4, 2011)

Author Contributions: Both authors contributed equally to this work. They both drafted parts of the manuscript and worked together on the whole paper.

Correspondence and requests for reprints should be addressed to Marius M. Hoeper, M.D., Hannover Medical School, Department of Respiratory Medicine, Carl-Neuberg-Strasse, 30625 Hannover, Germany. E-mail: hoeper.marius@mh-hannover.de

Copyright ©2011 by the American Thoracic Society

Am J Respir Crit Care Med Vol 184, pp 1114–1124, 2011

Originally Published in Press as DOI: 10.1164/rccm.201104-0662CI on June 23, 2011

Internet address: www.atsjournals.org

TABLE 1. UPDATED CLINICAL CLASSIFICATION OF PULMONARY HYPERTENSION

1. Pulmonary arterial hypertension (PAH)
 - 1.1. Idiopathic PAH
 - 1.2. Heritable
 - 1.2.1. BMPR2
 - 1.2.2. ALK1, endoglin (with or without hereditary hemorrhagic telangiectasia)
 - 1.2.3. Unknown
 - 1.3. Drugs and toxins induced
 - 1.4. Associated with
 - 1.4.1. Connective tissue diseases
 - 1.4.2. HIV infection
 - 1.4.3. Portal hypertension
 - 1.4.4. Congenital heart diseases
 - 1.4.5. Schistosomiasis
 - 1.4.6. Chronic hemolytic anemia
 - 1.5. Persistent pulmonary hypertension of the newborn
- 1'. Pulmonary venoocclusive disease and/or pulmonary capillary hemangiomatosis
2. Pulmonary hypertension due to left heart disease
 - 2.1. Systolic dysfunction
 - 2.2. Diastolic dysfunction
 - 2.3. Valvular disease
3. Pulmonary hypertension due to lung diseases and/or hypoxia
 - 3.1. Chronic obstructive pulmonary disease
 - 3.2. Interstitial lung disease
 - 3.3. Other pulmonary diseases with mixed restrictive and obstructive pattern
 - 3.4. Sleep-disordered breathing
 - 3.5. alveolar hypoventilation disorders
 - 3.6. Chronic exposure to high altitude
 - 3.7. Developmental abnormalities
4. Chronic thromboembolic pulmonary hypertension
5. PH with unclear and/or multifactorial mechanisms
 - 5.1. Hematological disorders: myeloproliferative disorders, splenectomy.
 - 5.2. Systemic disorders: sarcoidosis, pulmonary Langerhans cell histiocytosis, lymphangioleiomyomatosis, neurofibromatosis, vasculitis
 - 5.3. Metabolic disorders: glycogen storage disease, Gaucher disease, thyroid disorders
 - 5.4. Others: tumoral obstruction, fibrosing mediastinitis, chronic renal failure on dialysis

Definition of abbreviations: ALK1 = activin receptor-like kinase-1 gene; BMPR2 = bone morphogenetic protein receptor-2 gene; PH = pulmonary hypertension. From Reference 2.

normal conditions, allows the ejection of the RV to be augmented by left ventricular ejection (20, 21). Although highly efficient, the naive RV poorly adapts to sudden increases in afterload (Figure 1). An increase in RV end-diastolic volumes likely initially improves cardiac output by the Frank-Starling mechanism; however, a severe and sudden increase in right ventricular afterload may overwhelm the contractile capability of the RV and lead to hemodynamic collapse (16, 22–26). Ventriculoarterial coupling is a major determinant of RV function as it relates RV end-systolic elastance (a load-independent measure of contractility) relative to pulmonary arterial elastance (difference in end-systolic and end-diastolic RV pressure relative to stroke volume) (27–30). Normal coupling represents a point at which there is adequate flow output at the lowest energy cost. Patients with pulmonary hypertension may have a reduction in RV elastance relative to PA elastance, and the development of RV failure may be defined as a progressive disruption of the normal ventriculoarterial coupling (27). When RV afterload increases more gradually, RV adaptation occurs (31, 32). In an animal model of acute RV afterload, RV adaptation was observed within 96 hours (33). This adaptive myocardial hypertrophy is thought to reduce wall stress and maintain an adequate stroke volume (32, 34–37). However, in the face of a progressive or sudden worsening in RV afterload these compensatory mechanisms are overwhelmed.

A reduction in oxygen delivery in PAH may be mediated through two mechanisms. First, it may result from a decrease in

LV filling resulting from reduction in pulmonary blood flow. Second, RV enlargement may lead to reduced LV filling because of direct RV impingement on LV filling mediated by septal wall motion displacement by a pressure- and volume-overloaded RV (15, 20, 38–41). In both acute and chronic pulmonary hypertension, this adverse effect on left ventricular filling has been shown to be augmented by an increase in pericardial pressure caused by an enlarged RV (42). In this instance an elevation in right atrial pressure (a reasonable surrogate for pericardial pressure) should raise the possibility that changes in pulmonary capillary wedge pressure (PCWP) will be an unreliable estimate of LV preload. As such it becomes important for the clinician to consider transmural pressure (left ventricular end-diastolic pressure – pericardial pressure) as a more accurate reflection of LV filling. Practically, transmural pressure may be estimated as PCWP – right atrial (RA) pressure (42). It is important to recognize that in this adverse situation, volume loading may paradoxically lead to a reduction in left ventricular filling (43). Conversely, a reduction in right ventricular volume (mediated through diuresis) may improve left ventricular filling and cardiac output through a reduction in pericardial pressure and reduced influence of septal displacement. In this volume-overloaded state both RV filling and LV filling are also highly susceptible to the deleterious effects of tachycardia and tachyarrhythmia, which may further reduce LV filling and stroke volume (39). Last, prolongation of RV contraction causes RV contraction to continue beyond LV contraction, with resultant RV systolic encroachment on LV filling (44). This adverse ventricular interaction may be further enhanced through prolongation of RV contraction. This prolongation causes RV contraction to continue beyond LV contraction, resulting in RV systolic encroachment on LV filling (44). RV coronary blood flow also decreases as RV wall tension increases (45). Acute increases in wall tension may lead to RV ischemia and hemodynamic collapse. More sustained regional ischemia may lead to focal fibrosis, particularly at the insertion sites of the RV free wall on the interventricular septum.

FACTORS TRIGGERING RIGHT VENTRICULAR FAILURE IN PATIENTS WITH PULMONARY HYPERTENSION

Progressive obliteration of the pulmonary vascular bed inevitably results in RV failure once the adaptive mechanisms of the RV are exhausted (46). Contemporary treatment with endothelin receptor antagonists, phosphodiesterase (PDE)-5 inhibitors, and prostacyclin derivatives can sometimes slow disease progression in patients with PAH; however, mortality remains high in this patient population (47–49). Hence, RV failure is frequently encountered as a manifestation of disease progression despite targeted therapy. In many instances, however, triggering factors causing or aggravating RV failure can be identified, especially infections, anemia, trauma, surgery, pregnancy, nonadherence with therapy, pulmonary embolism, and arrhythmias (50). Identifying and treating these conditions is critical. A French series of 46 patients with PAH admitted to the ICU for RV failure (50) found a triggering factor in 19 (41%) patients, including unplanned withdrawal of PAH-targeted therapy ($n = 3$) or diuretics ($n = 1$), pregnancy ($n = 1$), septicemia ($n = 7$), pneumonia ($n = 3$), and arrhythmia ($n = 3$). Documented infection at any time during the ICU stay was the strongest predictor of death, occurring in 74% of the nonsurvivors compared with 22% of the survivors ($P = 0.0005$), and underscoring the need for aggressive management of infectious complications in these patients. It is likely that the bowel is a major source of bacteremia and endotoxemia in patients with pulmonary hypertension, as the combination of low cardiac output and elevated venous pressures may result in a loss of the intestinal barrier function (51, 52).

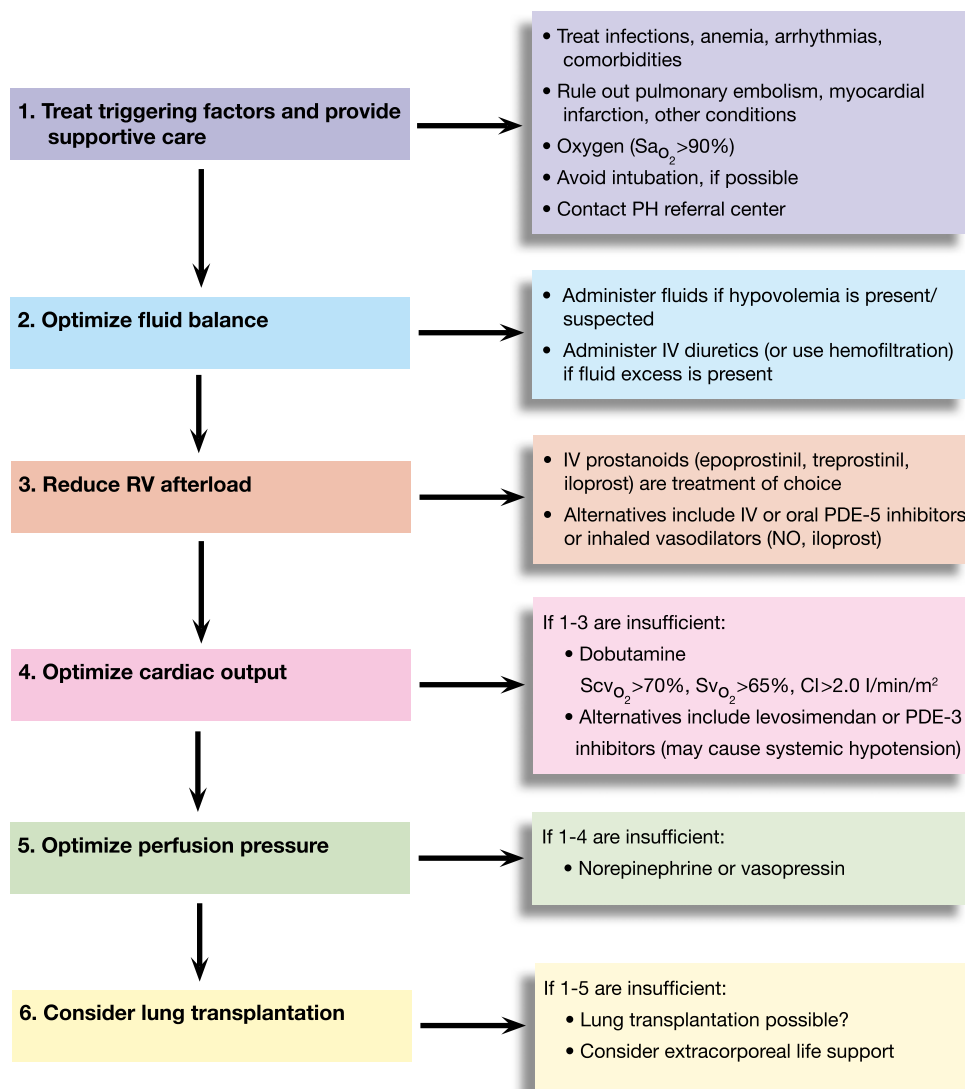


Figure 1. Hemodynamic management of critically ill patients with right ventricular failure due to pulmonary arterial hypertension. Which measures are necessary will depend on the individual patient. On many occasions, these treatment strategies need to be administered simultaneously rather than sequentially. CI = cardiac index; IV = intravenous; PDE-5 = phosphodiesterase-5; PH = pulmonary hypertension; RV = right ventricular; ScvO_2 = central venous oxygen saturation; SvO_2 = mixed venous oxygen saturation.

Arrhythmias are another treatable cause of RV failure in patients with PH. Whereas ventricular arrhythmias, especially ventricular flutter and ventricular fibrillation, have rarely been reported in these patients (53), atrial tachyarrhythmia (most importantly atrial tachycardia), atrial flutter, and atrial fibrillation are increasingly encountered (54). As augmented atrial contractility is an important compensatory mechanism in patients with a noncompliant RV (55), the loss of atrial contractions may have deleterious consequences for RV function. In patients with advanced PAH, new-onset atrial flutter or atrial fibrillation almost invariably results in RV failure. The management of supraventricular tachyarrhythmia in patients with PH has never been evaluated in clinical trials, but clinical experience indicates that the strategies derived from patients with left heart disease may not be fully applicable to patients with PH. Most importantly, rate control alone does not appear to be sufficient and restoration of sinus rhythm seems to be critical (54). Antiarrhythmics or electrical cardioversion may be required when patients are acutely unstable or have a new onset of arrhythmia. Atrial fibrillation is typically more difficult to treat than flutter. In general, β -blocking agents and calcium channel blockers should be avoided as they may further impair RV function. Digitalis glycosides are of limited value but may be used for rate control. In our centers, electrical cardioversion of new-onset atrial fibrillation is almost always attempted,

usually after pretreatment with amiodarone, which is then continued indefinitely to prevent relapse. The treatment of choice for refractory atrial flutter or atrial tachycardias is radiofrequency ablation.

MONITORING ON THE ICU

Evaluation of cardiac function as well as end-organ function is critical in managing patients with RV failure (Table 2). Measurements of renal, liver, and neurological function will provide some information about the adequacy of cardiac function and tissue perfusion. Echocardiography may be useful in the acute setting; however, the quantification of RV function by this method is thwarted by the nonsymmetrical shape of the RV, making it difficult to reproducibly assess RV contractility or volume. Other echocardiographic measures including tricuspid annular plane excursion and the Tei index, have been shown to be potentially valuable measures in monitoring patients with PAH (56–58). The degree of RV influence on LV size can be quantified by the deformity index, essentially a measure of the degree of septal bowing (59). However, the utility of these echocardiographic measures in the acute care setting has not been evaluated. Other methods including tissue Doppler and three-dimensional echocardiography remain potentially valuable methods for assessing RV function in the clinical setting, but

TABLE 2. RECOMMENDED MONITORING OF THE CRITICALLY ILL PATIENT WITH SEVERE PULMONARY ARTERIAL HYPERTENSION

Parameter	Modality	Treatment Goal
Renal function	Urinary catheter Serum creatinine	Maintain kidney function and diuresis. In general a net negative fluid balance is required
Liver function	AST, ALT, bilirubin	Reduce hepatic congestion Maintain hepatic perfusion
Cardiac function	Central venous line (central venous pressure, ScvO ₂) Pulmonary arterial catheter (RA pressure, cardiac index, PAPm, PVR, SvO ₂) Echocardiography	Improvement in cardiac function demonstrated by an increase in cardiac output with improvement (reduction) in right atrial pressures ScvO ₂ > 70% SvO ₂ > 65% Improve LV filling
Tissue perfusion/oxygenation	Lactate	<2.0 mmol/L
Neurohormonal markers	Brain natriuretic peptides (BNP or NT-proBNP)	Reduction in BNP levels
Myocardial perfusion	Systemic blood pressure (noninvasive or invasive) ECG Troponin	Ensure adequate systemic diastolic pressure (>60 mm Hg) Avoid/treat tachycardia/tachyarrhythmia Optimize myocardial perfusion (negative troponin)

Definition of abbreviations: ALT = alanine aminotransferase; AST = aspartate aminotransferase; BNP = brain natriuretic peptide; ECG = electrocardiogram; LV = left ventricle; NT-proBNP = N-terminal fragment of brain natriuretic peptide; PAPm = mean pulmonary arterial pressure; PVR = pulmonary vascular resistance; RA = right atrial; ScvO₂ = central venous oxygen saturation; SvO₂ = mixed venous oxygen saturation.

are not applicable for making repeated measures in hemodynamically unstable patients (60–62).

Studies have cast doubts on the utility of invasive measurement of cardiac function in critically ill patients with vasodilatory or cardiogenic shock (63, 64). However, for patients admitted to the ICU with severe PH and RV failure we advocate for the placement of invasive methods allowing for the measurement of RA pressure, left atrial pressure, cardiac output, and mixed-venous oxygen saturation (SvO₂). Measurement of pulmonary vascular resistance (PVR) is a composite index of pulmonary pressure and cardiac output. However, PVR may not accurately reflect right ventricular afterload. Unfortunately, more sophisticated measures of RV afterload are physiologically more relevant but generally not clinically feasible (28). Ultimately the success (or not) of a treatment strategy should be guided by the adequacy of tissue oxygen, which is partly reflected by measurements such as SvO₂ or central venous oxygen saturations (ScvO₂). Plasma lactate levels should be monitored closely, as elevated and/or increasing levels may signal progressive RV failure. The use of brain natriuretic peptide measurements to guide care may be of value to document trends in the adequacy of cardiac function over time, but may not provide sufficient real-time information to inform decisions about treatment in an unstable patient.

MANAGEMENT OF RV FAILURE IN PATIENTS WITH PULMONARY ARTERIAL HYPERTENSION

The management of RV failure in patients with PAH is complex and requires expertise. If such patients are admitted to nonspecialized centers a PH referral center should be contacted as soon as possible to discuss treatment options and possible interhospital transfer.

RV failure eventually results in multiorgan dysfunction. Reduced cardiac function can result in decreased bowel perfusion, loss of the intestinal barrier function, and bacterial translocation, a complication that has been implicated as a common cause of death in these patients (51, 54). Reduced hepatic perfusion can impair liver function or may even result in liver failure. Renal failure is another disastrous complication of RV failure.

The initial focus of care should center on addressing any potential reversible cause of acute RV decompensation (*see above*) and development of a strategy to improve RV function. The latter may be achieved through modifying RV preload, contractility, and afterload. Consideration must also be given to maintaining coronary perfusion and avoiding tachycardia (Table 2

and Figure 1). Meticulous fluid management, reducing venous filling pressures, and normalizing cardiac output are the main tools to recompensate these patients. The importance of appropriate hemodynamic monitoring has been outlined previously and close monitoring of blood pressure, urine production, RA pressure, and ScvO₂ or SvO₂ are crucial to guide treatment strategies in these patients.

Fluid Management

Fluid management of these patients is often difficult, as both hypovolemia and hypervolemia can have detrimental effects on blood pressure, organ perfusion, and cardiac function. Earlier studies have suggested that fluid loading may improve hemodynamics in patients with acute pulmonary embolism (65), but unmonitored fluid challenge may further impair RV function (*see above*). In most, but not all, cases, RV failure is associated with fluid overload and a negative fluid balance is the key to successful therapy. However, fluid removal may reduce the already low cardiac output and may thereby further impair end-organ function.

The ICU management of patients with predominantly diastolic dysfunction of the RV, elevated filling pressures, and fluid retention in the presence of normal or near-normal cardiac output and normal blood pressure is straightforward, as these patients can usually be managed with diuretic therapy.

Maintaining Cardiac Output and Systemic Blood Pressure

Systolic RV failure with low cardiac output and hypotension is more difficult to treat and may require catecholamines or vasopressin to stabilize blood pressure and cardiac output. The β_1 -agonist dobutamine augments myocardial contractility and reduces right and left ventricular afterload, which makes it the preferred catecholamine for patients with RV failure (12, 50). However, the use of β -adrenergic agents may lead to tachycardia. Patients with pulmonary hypertension may be particularly vulnerable to the adverse effects of tachycardia on diastolic filling time. Consequently, agents that do not have chronotropic properties, such as PDE-3 inhibitors, may be preferable in some patients. PDE-3 inhibitors may have direct inotropic effects by increasing levels of endogenous cAMP and indirectly augment cardiac function by reducing afterload. Although these agents received a high recommendation in the systematic review by Price and colleagues, most of the referenced studies were completed in patients with PH secondary to left ventricular failure, postventricular assist, or cardiac transplantation (11). Despite

potential advantages of these agents, systemic vasodilation may limit the use or require concomitant administration of a systemic vasoconstrictor such as norepinephrine. A few reports suggest that inhaled milrinone might be useful in RV failure, as this mode of application allows preferential pulmonary vasodilation without the risk of systemic hypotension (66, 67).

Profound or persistent hypotension, especially in patients with low systemic vascular resistance due to infection, may require additional therapy with norepinephrine, a vasoconstrictor stimulating α_1 - and β_1 -adrenergic receptors. Adequate systemic blood pressure is required to ensure adequate coronary perfusion in these patients, which is a prerequisite to maintain cardiac function (68). Furthermore, there is a suggestion that an increase in LV afterload may improve the adverse conformational shape that the dilated RV imposes on an underfilled LV. The downside of higher doses of norepinephrine is its potential detrimental effect on pulmonary vascular resistance (69). Vasopressin may be an alternative to norepinephrine as this drug has systemic vasoconstrictive but pulmonary vasodilatory properties, but there are few clinical data supporting its use in patients with pulmonary hypertension (70–72). Levosimendan, a calcium-sensitizing agent with positive inotropic and vasodilatory effects, holds promise for patients with PH and RV failure (73, 74), but it has not yet been thoroughly investigated in these patients (75–78).

Oxygen and Ventilator Support

Maintaining sufficient oxygen supply is self-evident. This includes supplemental oxygen to keep peripheral oxygen saturation above 90% and the correction of anemia, if present. The ideal hemoglobin level of patients with RV failure due to PH has never been studied, but given the likelihood that anemia (and even isolated iron deficiency) may worsen RV function, we suggest that hemoglobin levels greater than 10 g/dl be maintained (79).

Every attempt should be made to avoid endotracheal intubation of patients with RV failure (80). Intubation of these patients is often problematic owing to effects of sedatives on cardiac function and nonselective vasodilation leading to systemic hypotension and hemodynamic collapse.

Continuous positive airway pressure or noninvasive ventilation may be considered, but opioids or sedatives should be administered with great care to avoid drops in blood pressure. If intubation and mechanical ventilation are unavoidable, hypotension and loss of RV contractility must be prevented and the administration of catecholamines before anesthesia should be considered. Despite the lack of controlled clinical trials, etomidate is the preferred drug for induction of general anesthesia as it has little effect on cardiac contractility and vascular tone (81, 82). Maintenance of anesthesia is usually achieved with low-dose opioids or ketamine together with benzodiazepines or propofol. Airway pressures should be kept to a minimum while at the same time hypercapnia must be prevented because of its deleterious effects on pulmonary hemodynamics (12, 83, 84). Attempts at cardiopulmonary resuscitation remain largely unsuccessful in patients with PAH and RV failure (53).

Percutaneous Interventions

The presence of large pericardial effusions is associated with a poor prognosis in patients with pulmonary arterial hypertension, but the presence of tamponade may be difficult to determine on the basis of typical echocardiographic criteria. In general, draining pericardial effusions should be avoided. Although anecdotal case reports suggest that opening of the pericardium may improve cardiac function (85), two small series reported 50% mortality in patients who had their effusion drained (86, 87).

Balloon atrioseptostomy (BAS) is used in some pulmonary hypertension centers as treatment of severe pulmonary hypertension. BAS decompresses the enlarged RV and improves LV filling as well as cardiac output. Despite oxygen desaturation, the net effect is usually an increase in systemic oxygen transport (88). In experienced centers BAS is considered a safe procedure as long as it is performed in hemodynamically stable patients (89). However, BAS is not recommended as an emergency procedure for patients with RV failure, as the risk of fatal complications is high in patients with markedly elevated RV-filling pressures (RA pressure > 20 mm Hg) and/or low oxygen saturations (not recommended for patients with O_2 saturation at rest < 80% on room air) (6).

Reducing RV Afterload

One of the most important interventions to reverse RV failure is to reduce RV afterload through the use of pulmonary vasodilators or PAH-targeted therapies. The importance of reducing RV afterload is emphasized by the rapidity with which RV function is restored after pulmonary endarterectomy and lung transplantation (90–93). The use of PAH-targeted therapies depends primarily on previous treatment. In therapy-naïve patients with PAH (or other severe forms of PH) and RV failure, intravenous prostacyclin derivatives (epoprostenol, treprostinil, iloprost) are the initial treatment of choice, although care must be taken to avoid systemic hypotension. It needs to be emphasized that intravenous epoprostenol remains the only PAH therapy for which improved survival has been demonstrated in a randomized, controlled clinical trial. Once these patients have been stabilized, oral therapies with endothelin receptor antagonists and PDE-5 inhibitors may be added with or without later withdrawal of the prostanoid. Intravenous prostacyclin derivatives are also the preferred therapy for patients who have been pretreated with nonparenteral drugs, although the clinical response is sometimes less impressive than in treatment-naïve patients. Inhaled vasodilators such as nitric oxide or iloprost might be used as supplementary therapy (94–96), especially in patients who do not tolerate parenteral prostanoids because of systemic hypotension. Inhaled NO is frequently used in intubated patients, for instance, in patients with PH and RV failure after cardiac surgery (97–99). Oral drugs, especially endothelin receptor antagonists and phosphodiesterase-5 inhibitors, have not been investigated in the setting of RV failure and are usually not recommended as initial treatment. An intravenous formulation of the PDE-5 inhibitor sildenafil has become available that might be useful in the ICU management of RV failure, but it also needs to be further evaluated, especially regarding the risks of systemic hypotension (100). Nonspecific vasodilators such as calcium channel blockers may cause profound systemic hypotension and should therefore be avoided in patients with RV failure.

For patients in whom all conventional treatment options including intravenous prostacyclin derivatives have been exhausted, ICU treatment will have to rely primarily on the general measures outlined previously, focusing on careful fluid management and a judicious choice of catecholamines. In these dire cases, the outcome will depend mostly on whether triggering factors can be identified and corrected, and whether transplantation is a potential option (*see below*).

SPECIAL CONSIDERATIONS FOR OTHER FORMS OF PULMONARY HYPERTENSION

PAH Subpopulations

PAH, the prototype of PH, is generally treated according to the above-mentioned considerations, and there are usually no

further specific treatment options. This is also true for most of the cases in which PAH is associated with connective tissue disease. One important exception are patients with systemic lupus erythematosus (SLE) and PAH. In these patients, flare-ups in lupus activity are often accompanied by worsening of PAH. Therefore aggressive immunosuppression in addition to PAH therapy should be considered if these patients present with evidence of clinically or serologically active SLE and RV failure. Although evidence to support this practice is limited to case reports, pulse steroids and either azathioprine or cyclophosphamide are commonly used in these patients (101).

PH Associated with Left Heart Disease

Patients with systolic left ventricular dysfunction may have an increase in RV afterload due to a passive increase in pulmonary pressure resulting from an increase in left ventricular end-diastolic pressure and, variably, an active component relating to an increase in transpulmonary gradient (mean pulmonary arterial pressure – PCWP). In these patients, treatment should focus on strategies to improve left ventricular function through manipulating preload, contractility, and afterload. However, even after successful treatment and a reduction in left atrial/left ventricular end-diastolic pressure, the transpulmonary gradient may remain elevated. This is particularly relevant for patients who are being considered for heart transplantation or left ventricular assist device placement, where the presence of a refractory elevation in PVR and RV dysfunction may disqualify them for transplantation or lead to a requirement for mechanical RV support. Although initial reports have suggested that pulmonary vasodilators may have led to harm in patients with LV dysfunction and PH, more recent studies in patients with a persistently elevated transpulmonary gradient despite medically optimized LV function or mechanical support have shown benefit from pulmonary vasodilators such as sildenafil (102). However, further studies are needed to assess whether this leads to improved outcome. Aside from these unique settings, pulmonary vasodilators currently play no role in the ICU management of patients with left heart failure, even if they suffer from pulmonary hypertension.

PH Associated with Lung Disease

Although pulmonary hypertension may complicate acute respiratory distress syndrome, it is typically not hemodynamically relevant to patients without preexisting PAH and usually does not require specific treatment. In patients with PH in the setting of obstructive, fibrotic, or hypoventilation syndromes, treatment generally centers around correcting hypoxemia and hypercapnia. Patients presenting with hypercapnic respiratory failure and PH with signs of RV failure often recover rapidly on standard therapy including noninvasive ventilation. No pulmonary vasodilator therapy has been systematically evaluated in these patients. Indeed, the use of pulmonary vasodilators in the treatment of these conditions is controversial as they may further impair gas exchange.

Chronic Thromboembolic Pulmonary Hypertension

Patients with CTEPH presenting with RV failure are generally treated according to the same principles outlined previously. One important consideration is the likelihood of a new episode of acute pulmonary embolism. Even small pulmonary emboli may cause hemodynamic deterioration in patients with preexisting pulmonary hypertension, and it is often impossible to distinguish old from new thrombotic material on a computed tomographic scan. Old thrombotic material is fully organized and therefore not amenable to medical therapy, but fibrinolytic

therapy may be considered if there is a high likelihood of an acute-on-chronic event. If patients with CTEPH cannot be stabilized by medical therapy, emergency pulmonary endarterectomy should be considered (103). Of note, this procedure is different from pulmonary embolectomy and requires surgical expertise that is available only in specialized centers.

Pulmonary Venooclusive Disease

Pulmonary venooclusive disease represents a significant challenge. This diagnosis should be suspected in a patient who satisfies the diagnostic criteria for idiopathic pulmonary arterial hypertension but who has computed tomographic evidence of patchy ground-glass opacities, septal lines, pleural effusions, and/or mediastinal adenopathy (104, 105). It is important to emphasize that the pulmonary capillary wedge pressure is often normal in these patients, as disease relates to an increase in pulmonary venous vascular resistance and not alterations in left atrial compliance. Therefore in a zero-flow state (after balloon occlusion) the effect of the high venous resistance to flow is not measured. These patients may also have significant hypoxemia from the resultant interstitial and alveolar edema. It is important to recognize that classical pulmonary vasodilators may improve cardiac output but worsen lung edema (106, 107). Apart from attempts at aggressive diuresis there is no temporizing therapy available for these patients. Even though some patients with pulmonary venooclusive disease may show a transient response to pulmonary vasodilators, the only definitive treatment for these patients is lung transplantation.

LUNG TRANSPLANTATION, BRIDGING, AND EXTRACORPOREAL LIFE SUPPORT

Despite advances in medical therapy, lung or heart–lung transplantation (H/LTx) remains an important treatment option for patients with progressive PH, especially for patients with refractory RV failure (108). A review of patient selection and of indications and contraindications for H/LTx is beyond the scope of this article and has been addressed elsewhere (109). For patients requiring ICU care for PAH and RV failure, several important decisions regarding transplantation need to be made: (1) Is the patient suffering from end-stage RV failure not responding to optimized medical therapy? (2) Provided the answer to the first question is yes, is the patient a potential candidate for H/LTx, and is it possible to realize transplantation in a reasonable time frame (what is reasonable will depend on patient factors as well as local organ allocation rules and organ availability)? (3) If the answer to the second item is also yes, may the patient benefit from extracorporeal life support (ECLS)?

Once a decision to proceed with H/LTx has been made, the treatment strategies described previously become bridging strategies. Maintaining cardiac output and preventing secondary organ failure are the most important objectives, but the means to establish these objectives in patients with end-stage disease are limited. The use of ECLS has become the preferred bridging strategy for patients with RV failure in some high-volume transplantation centers (110–113). With appropriate ECLS, the RV is immediately unloaded; PAH therapy and catecholamines are usually no longer required; and the perfusion of other organs, especially bowel, liver, and kidneys, dramatically improves. ECLS should therefore be considered in patients with refractory hypotension and/or signs of progressive secondary organ dysfunction, at least when prompt transplantation is a realistic option.

Several advances have led to renewed interest in, and hitherto unseen success of, ECLS as a bridge to transplantation: the development of improved devices with centrifugal blood pumps and low-resistance, heparin-coated biocompatible oxygenators

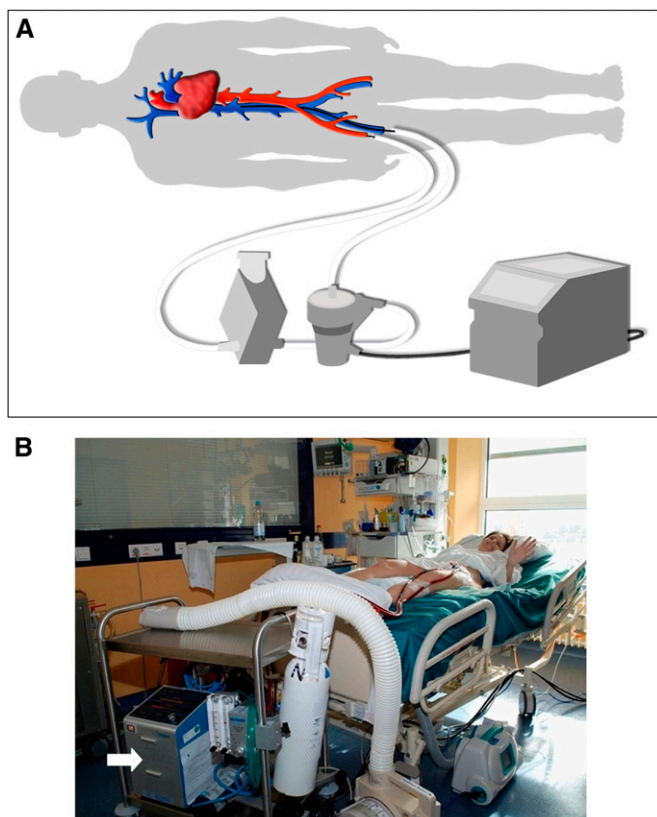


Figure 2. The schematic shows the concept of venoarterial extracorporeal membrane oxygenation (v/a ECMO). (A) Blood is withdrawn from the right atrium, oxygenated, and returned into the lower abdominal aorta. (B) A patient with idiopathic pulmonary arterial hypertension and right ventricular failure receiving v/a ECMO support. The oxygenator is not visible, as it is hidden behind the ECMO control panel (white arrow). The venous cannula is inserted via the left femoral vein into the right atrium, from which the blood is removed and pumped through the oxygenator back into the arterial cannula placed into the right femoral artery. The patient received ECMO support for 42 days before she underwent successful bilateral lung transplantation. The patient provided written permission for this photograph to be published.

and the application of ECLS devices in awake, nonintubated patients (112) as well as the use of pumpless devices inserted between the pulmonary artery and the left atrium (113). However, long-term use of ECLS requires intense anticoagulation and bleeding problems remain a main source of complication in patients treated with such devices.

Venoarterial ECMO in Nonintubated Patients As a Bridge to Transplantation

Venoarterial extracorporeal membrane oxygenation (v/a ECMO) has been attempted as a bridge to transplantation in intubated patients with RV failure. These patients were exposed not only to the risks associated with ECMO but also to the risks and complications of prolonged sedation and mechanical ventilation, especially pneumonia and septicemia. Not surprisingly, the outcomes associated with this strategy were sobering.

The group from Hannover Medical School (Hannover, Germany) reported on a series of five patients with RV failure who were treated by v/a ECMO while awake and breathing spontaneously (112). All patients had severe cardiopulmonary failure and were deemed moribund, but rapid improvement occurred after ECMO implantation, including an almost immediate recovery

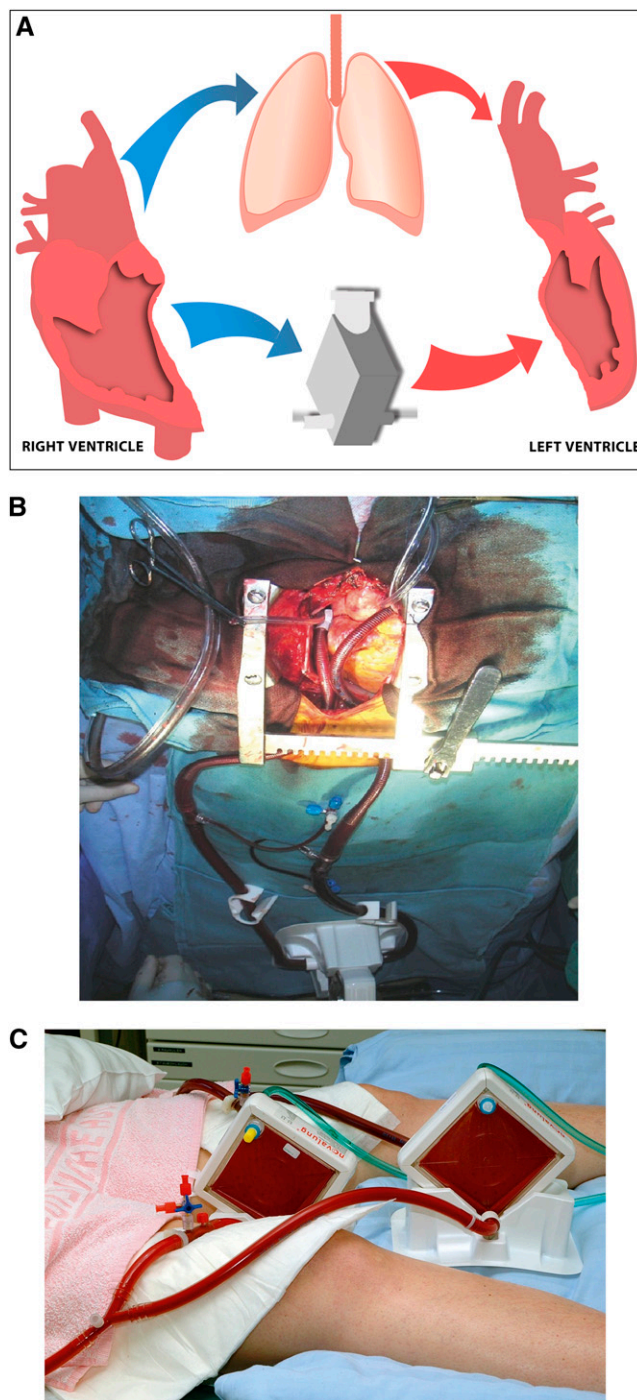


Figure 3. (A) The membrane oxygenator is interposed between the pulmonary artery and the left atrium and blood is pumped from the right ventricle through the membrane oxygenator and returns to the left atrium. Most of the cardiac output flows through the low resistance Novalung circuit, with little blood flowing through the native pulmonary circuit. (B) Photograph of the membrane oxygenator being used in a patient with pulmonary arterial hypertension and right ventricular failure. The circuit is inserted between the pulmonary artery and the left atrium. The blood is driven by the right ventricle and no pump is needed. (C) In some cases two membrane oxygenator devices are interposed in the circulation to avoid complications in cases of device failure.

of renal function in those patients who presented with kidney failure. Four patients were successfully bridged to transplantation after 18–35 days on ECMO support and three of them were

successfully transplanted and survived for more than 1 year. This small case series demonstrated the feasibility of v/a ECMO in patients with terminal RV failure, offering a salvage strategy for these patients if other treatments fail. The main disadvantages of v/a ECMO include the risk of bleeding complications related to anticoagulation and the fact that the patients cannot be fully mobilized with the device in place (Figure 2).

Pumpless Lung Assist Devices Inserted into the Pulmonary Circulation

An alternative bridging strategy is the use of a pumpless device inserted between the pulmonary arteries and the left atrium (PA–LA). The first report on the successful application of the PA–LA approach was published by groups from Germany and Canada (113, 114). They used an interventional lung assist device designed by Novalung (Hechingen, Germany), a low-resistance membrane oxygenator, originally developed for insertion between a femoral artery and a femoral vein to allow extracorporeal CO₂ removal (110, 111, 115) (Figure 3). In patients with PAH, the device was connected between the main pulmonary artery and the left atrium. The patient's RV drives blood flow through the device, thus obviating the need for a pump.

The insertion of this device requires general anesthesia, intubation, mechanical ventilation, and sternotomy. The centers using this technique so far prefer to place the patients on v/a ECMO before the procedure to avoid hemodynamic instability after intubation. The ECMO cannulas are later removed once blood flow through the Novalung device has been established. As with v/a ECMO, this approach results in immediate stabilization of hemodynamics and gas exchange. Most of the patients can be extubated after the procedure. The insertion of the PA–LA device is more elaborate than implanting a v/a ECMO. However, the PA–LA approach requires no blood pump and the patients can be fully mobilized. In addition, this technique leads to reconditioning of the deprived and stiff left ventricle, which may help to avoid complications after the transplantation.

ETHICAL CONSIDERATIONS AND END-OF-LIFE CARE

Ideally, questions related to prognosis, the possibility of transplantation, and patient's wishes concerning end-of-life care should be discussed in a calm atmosphere between the patient, his family, and his caregivers during the course of the disease. The ICU is not the best setting to address these complex questions for the first time, especially as decisions often need to be made rapidly. In patients with end-stage PH in whom all available treatment options have been exhausted, limitations on advanced treatments should be considered and discussed with the patient and/or his relatives, when appropriate. This may imply the decision not to admit a patient to the ICU if the prognosis is poor. In such cases, providing comfort and symptom relief may become the main objectives, as in other patients approaching the end of their lives.

Novel technical developments such as ECLS may create hope but at the same time new ethical dilemmas. So far predominantly used as a bridge to transplantation, ECLS may also be considered a bridge to recovery in patients with treatable triggers of RV failure. Without the perspective of transplantation, however, ECLS strategies will frequently fail, which may result in complex decisions about if and when to conclude this treatment. Similar problems will arise when ECLS devices are being used in pregnant patients (116). Although this strategy may stabilize the mother for weeks or even months, thus allowing maturation of the fetus and successful delivery, there is a high likelihood that it will be impossible to wean the mother from the device, causing immense psychological problems for the patient, her

family, and her caregivers. In the future, ECLS systems may be used as a bridge to destiny similar to left ventricular assist devices in patients with LV failure. Although fascinating and appealing, these developments will be accompanied by failures, drawbacks, and devastating complications.

SUMMARY AND OUTLOOK

Despite advances in medical therapy, PAH remains a lethal condition for many patients. With disease progression, the marginalized right ventricle is susceptible to failure. Owing to the expertise required to manage these patients, their inherent complexity, and resource requirements, these patients are best managed in experienced centers (10). The principles of care should focus on improving RV function and oxygen delivery to prevent the development of multiorgan failure, by optimizing preload, reducing afterload, and improving RV contractility. Preservation of coronary blood flow and avoiding treatment-induced increases in heart rate should also guide treatment decisions. Unfortunately, there are few data to guide clinicians on the best pharmacological therapies in these patients. There is a clear need to improve our understanding of RV adaptation and develop strategies to avoid RV decompensation (117). At present, most of the data are derived from animal models of pulmonary hypertension. Treatment decisions therefore are based on biological plausibility and clinical experience. Extracorporeal support is currently regarded as a bridge to lung transplantation, but may one day become a destination therapy. Lung transplantation and pulmonary endarterectomy remain definitive destination therapies in select patients who are eligible for these surgical treatments. Patients who are not eligible for destination therapy need to be counseled in advance to ensure that discussions regarding treatment options, end-of-life decision-making, and, when appropriate, palliative measures are instituted.

Author Disclosure: M.M.H. has received consulting fees from Actelion, Bayer, Gilead, GlaxoSmithKline (GSK), Lilly, Pfizer, and Novartis; he has received travel support from Actelion, Bayer, Gilead, GSK, Lilly, and Pfizer; he has received lecture fees from Actelion, Bayer, GSK, Lilly, and Pfizer. J.G. has received consultancy fees from Actelion, GSK, and Lilly; he has received expert witness fees from Pfizer; he has received travel support from Actelion; his institution has received grants from Actelion and Pfizer; he and his institution have received lecture fees from Actelion; his institution has received lecture fees from Lilly and GSK; his institution has received payment for development of educational presentations from Actelion, Pfizer, GSK, United, and Lilly.

References

1. D'Alonzo GE, Barst RJ, Ayres SM, Bergofsky EH, Brundage BH, Detre KM, Fishman AP, Goldring RM, Groves BM, Kernis JT, *et al*. Survival in patients with primary pulmonary hypertension: results from a national prospective registry. *Ann Intern Med* 1991;115:343–349.
2. Simonneau G, Robbins IM, Beghetti M, Channick RN, Delcroix M, Denton CP, Elliott CG, Gaine SP, Gladwin MT, Jing ZC, *et al*. Updated clinical classification of pulmonary hypertension. *J Am Coll Cardiol* 2009;54:S43–S54.
3. Galie N, Hoeper MM, Humbert M, Torbicki A, Vachiery JL, Barbera JA, Beghetti M, Corris P, Gaine S, Gibbs JS, *et al*. Guidelines for the diagnosis and treatment of pulmonary hypertension. The Task Force for the Diagnosis and Treatment of Pulmonary Hypertension of the European Society of Cardiology (ESC) and the European Respiratory Society (ERS), endorsed by the International Society of Heart and Lung Transplantation (ISHLT). *Eur Respir J* 2009;34:1219–1263.
4. Faughnan M, Young L, Granton J. Pulmonary manifestations of hereditary hemorrhagic telangiectasia. *Eur Respir J* (In press)
5. Machado RF, Gladwin MT. Chronic sickle cell lung disease: new insights into the diagnosis, pathogenesis and treatment of pulmonary hypertension. *Br J Haematol* 2005;129:449–464.
6. Galie N, Hoeper MM, Humbert M, Torbicki A, Vachiery JL, Barbera JA, Beghetti M, Corris P, Gaine S, Gibbs JS, *et al*. Guidelines for the diagnosis and treatment of pulmonary hypertension: The Task

- Force for the Diagnosis and Treatment of Pulmonary Hypertension of the European Society of Cardiology (ESC) and the European Respiratory Society (ERS), endorsed by the International Society of Heart and Lung Transplantation (ISHLT). *Eur Heart J* 2009;30:2493–2537.
7. Badesch DB, Abman SH, Simonneau G, Rubin LJ, McLaughlin VV. Medical therapy for pulmonary arterial hypertension: updated ACCP evidence-based clinical practice guidelines. *Chest* 2007;131:1917–1928.
 8. McLaughlin VV, Archer SL, Badesch DB, Barst RJ, Farber HW, Lindner JR, Mathier MA, McGoon MD, Park MH, Rosenson RS, et al. ACCF/AHA 2009 expert consensus document on pulmonary hypertension: a report of the American College of Cardiology Foundation Task Force on Expert Consensus Documents and the American Heart Association developed in collaboration with the American College of Chest Physicians; American Thoracic Society, Inc.; and the Pulmonary Hypertension Association. *J Am Coll Cardiol* 2009;53:1573–1619.
 9. McLaughlin VV, Archer SL, Badesch DB, Barst RJ, Farber HW, Lindner JR, Mathier MA, McGoon MD, Park MH, Rosenson RS, et al. ACCF/AHA 2009 expert consensus document on pulmonary hypertension: a report of the American College of Cardiology Foundation Task Force on Expert Consensus Documents and the American Heart Association: Developed in collaboration with the American College of Chest Physicians, American Thoracic Society, Inc.; and the Pulmonary Hypertension Association. *Circulation* 2009;119:2250–2294.
 10. Delcroix M, Naeije R. Optimising the management of pulmonary arterial hypertension patients: emergency treatments. *Eur Respir Rev* 2010;19:204–211.
 11. Price LC, Wort SJ, Finney SJ, Marino PS, Brett SJ. Pulmonary vascular and right ventricular dysfunction in adult critical care: current and emerging options for management: a systematic literature review. *Crit Care* 2010;14:R169.
 12. Zamanian RT, Haddad F, Doyle RL, Weinacker AB. Management strategies for patients with pulmonary hypertension in the intensive care unit. *Crit Care Med* 2007;35:2037–2050.
 13. Via G, Braschi A. Pathophysiology of severe pulmonary hypertension in the critically ill patient. *Minerva Anesthesiol* 2004;70:233–237.
 14. Chin KM, Kim NH, Rubin LJ. The right ventricle in pulmonary hypertension. *Coron Artery Dis* 2005;16:13–18.
 15. Greyson CR. The right ventricle and pulmonary circulation: basic concepts. *Rev Esp Cardiol* 2010;63:81–95.
 16. Redington AN, Rigby ML, Shinebourne EA, Oldershaw PJ. Changes in the pressure–volume relation of the right ventricle when its loading conditions are modified. *Br Heart J* 1990;63:45–49.
 17. Sanchez-Quintana D, Climent V, Ho SY, Anderson RH. Myoarchitecture and connective tissue in hearts with tricuspid atresia. *Heart* 1999;81:182–191.
 18. Belenkie I, Sas R, Mitchell J, Smith ER, Tyberg JV. Opening the pericardium during pulmonary artery constriction improves cardiac function. *J Appl Physiol* 2004;96:917–922.
 19. Kroecker CA, Shrive NG, Belenkie I, Tyberg JV. Pericardium modulates left and right ventricular stroke volumes to compensate for sudden changes in atrial volume. *Am J Physiol Heart Circ Physiol* 2003;284:H2247–H2254.
 20. Hoffman D, Sisto D, Frater RW, Nikolic SD. Left-to-right ventricular interaction with a noncontracting right ventricle. *J Thorac Cardiovasc Surg* 1994;107:1496–1502.
 21. Santamore WP, Dell'Italia LJ. Ventricular interdependence: significant left ventricular contributions to right ventricular systolic function. *Prog Cardiovasc Dis* 1998;40:289–308.
 22. Bronicki RA, Baden HP. Pathophysiology of right ventricular failure in pulmonary hypertension. *Pediatr Crit Care Med* 2010;11:S15–S22.
 23. Matthews JC, McLaughlin V. Acute right ventricular failure in the setting of acute pulmonary embolism or chronic pulmonary hypertension: a detailed review of the pathophysiology, diagnosis, and management. *Curr Cardiol Rev* 2008;4:49–59.
 24. Mebazaa A, Karpati P, Renaud E, Algotsson L. Acute right ventricular failure—from pathophysiology to new treatments. *Intensive Care Med* 2004;30:185–196.
 25. Tan JL, Prati D, Gatzoulis MA, Gibson D, Henein MY, Li W. The right ventricular response to high afterload: comparison between atrial switch procedure, congenitally corrected transposition of the great arteries, and idiopathic pulmonary arterial hypertension. *Am Heart J* 2007;153:681–688.
 26. Watts JA, Marchick MR, Kline JA. Right ventricular heart failure from pulmonary embolism: key distinctions from chronic pulmonary hypertension. *J Card Fail* 2010;16:250–259.
 27. Brimiouille S, Wauthy P, Ewalenko P, Rondelet B, Vermeulen F, Kerbaul F, Naeije R. Single-beat estimation of right ventricular end-systolic pressure–volume relationship. *Am J Physiol Heart Circ Physiol* 2003;284:H1625–H1630.
 28. Champion HC, Michelakis ED, Hassoun PM. Comprehensive invasive and noninvasive approach to the right ventricle–pulmonary circulation unit: state of the art and clinical and research implications. *Circulation* 2009;120:992–1007.
 29. Chesler NC, Roldan A, Vanderpool RR, Naeije R. How to measure pulmonary vascular and right ventricular function. *Conf Proc IEEE Eng Med Biol Soc* 2009;2009:177–180.
 30. Fourie PR, Coetzee AR, Bolliger CT. Pulmonary artery compliance: its role in right ventricular–arterial coupling. *Cardiovasc Res* 1992;26:839–844.
 31. Sharma S, Taegtmeier H, Adroge J, Razeghi P, Sen S, Ngumbela K, Essop MF. Dynamic changes of gene expression in hypoxia-induced right ventricular hypertrophy. *Am J Physiol Heart Circ Physiol* 2004;286:H1185–H1192.
 32. Simon MA. Right ventricular adaptation to pressure overload. *Curr Opin Crit Care* 2010;16:237–243.
 33. Dias CA, Assad RS, Caneco LF, Abduch MC, Aiello VD, Dias AR, Marcial MB, Oliveira SA. Reversible pulmonary trunk banding. II. An experimental model for rapid pulmonary ventricular hypertrophy. *J Thorac Cardiovasc Surg* 2002;124:999–1006.
 34. Baandrup JD, Markvardsen LH, Peters CD, Schou UK, Jensen JL, Magnusson NE, Orntoft TF, Kruhoffer M, Simonsen U. Pressure load: the main factor for altered gene expression in right ventricular hypertrophy in chronic hypoxic rats. *PLoS ONE* 2011;6:e15859.
 35. Badano LP, Gingham C, Easaw J, Muraru D, Grillo MT, Lancellotti P, Pinamonti B, Coghlan G, Marra MP, Popescu BA, et al. Right ventricle in pulmonary arterial hypertension: haemodynamics, structural changes, imaging, and proposal of a study protocol aimed to assess remodelling and treatment effects. *Eur J Echocardiogr* 2010;11:27–37.
 36. Chen EP, Akhter SA, Bittner HB, Koch WJ, Davis RD, Van Trigt P III. Molecular and functional mechanisms of right ventricular adaptation in chronic pulmonary hypertension. *Ann Thorac Surg* 1999;67:1053–1058.
 37. Spindler M, Schmidt M, Geier O, Sandstede J, Hahn D, Ertl G, Beer M. Functional and metabolic recovery of the right ventricle during bosentan therapy in idiopathic pulmonary arterial hypertension. *J Cardiovasc Magn Reson* 2005;7:853–854.
 38. Faludi R, Komocsi A, Bozo J, Kumanovics G, Czirkaj L, Papp L, Simor T. Isolated diastolic dysfunction of right ventricle: stress-induced pulmonary hypertension. *Eur Respir J* 2008;31:475–476.
 39. Gan CT, Lankhaar JW, Marcus JT, Westerhof N, Marques KM, Bronzwaer JG, Boonstra A, Postmus PE, Vonk-Noordegraaf A. Impaired left ventricular filling due to right-to-left ventricular interaction in patients with pulmonary arterial hypertension. *Am J Physiol Heart Circ Physiol* 2006;290:H1528–H1533.
 40. Vonk-Noordegraaf A, Marcus JT, Gan CT, Boonstra A, Postmus PE. Interventricular mechanical asynchrony due to right ventricular pressure overload in pulmonary hypertension plays an important role in impaired left ventricular filling. *Chest* 2005;128:628S–630S.
 41. Yamaguchi S, Li KS, Harasawa H, Santamore WP. Acute alterations in systolic ventricular interdependence-mechanical dependence of right ventricle on left ventricle following acute alteration of right ventricular free wall. *Basic Res Cardiol* 1993;88:350–361.
 42. Belenkie I, Smith ER, Tyberg JV. Ventricular interaction: from bench to bedside. *Ann Med* 2001;33:236–241.
 43. Belenkie I, Dani R, Smith E, Tyberg J. Effects of volume loading during experimental acute pulmonary embolism. *Circulation* 1989;80:178–188.
 44. Handoko ML, Lamberts RR, Redout EM, de Man FS, Boer C, Simonides WS, Paulus WJ, Westerhof N, Allaart CP, Vonk-Noordegraaf A. Right ventricular pacing improves right heart function in

- experimental pulmonary arterial hypertension: a study in the isolated heart. *Am J Physiol Heart Circ Physiol* 2009;297:H1752–H1759.
45. Gibbons Kroeker CA, Adeeb S, Shrive NG, Tyberg JV. Compression induced by RV pressure overload decreases regional coronary blood flow in anesthetized dogs. *Am J Physiol Heart Circ Physiol* 2006;290: H2432–H2438.
 46. Bogaard HJ, Natarajan R, Henderson SC, Long CS, Kraskauskas D, Smithson L, Ockaili R, McCord JM, Voelkel NF. Chronic pulmonary artery pressure elevation is insufficient to explain right heart failure. *Circulation* 2009;120:1951–1960.
 47. Humbert M, Sitbon O, Yaici A, Montani D, O’Callaghan DS, Jais X, Parent F, Savale L, Natali D, Gunther S, *et al.* Survival in incident and prevalent cohorts of patients with pulmonary arterial hypertension. *Eur Respir J* 2010;36:549–555.
 48. Humbert M, Sitbon O, Chaouat A, Bertocchi M, Habib G, Gressin V, Yaici A, Weitzenblum E, Cordier JF, Chabot F, *et al.* Survival in patients with idiopathic, familial, and anorexigen-associated pulmonary arterial hypertension in the modern management era. *Circulation* 2010;122:156–163.
 49. Benza RL, Miller DP, Gomberg-Maitland M, Frantz RP, Foreman AJ, Coffey CS, Frost A, Barst RJ, Badesch DB, Elliott CG, *et al.* Predicting survival in pulmonary arterial hypertension: insights from the Registry to Evaluate Early and Long-term Pulmonary Arterial Hypertension Disease Management (REVEAL). *Circulation* 2010; 122:164–172.
 50. Sztrymf B, Souza R, Bertoletti L, Jais X, Sitbon O, Price LC, Simonneau G, Humbert M. Prognostic factors of acute heart failure in patients with pulmonary arterial hypertension. *Eur Respir J* 2010;35:1286–1293.
 51. Krack A, Sharma R, Figulla HR, Anker SD. The importance of the gastrointestinal system in the pathogenesis of heart failure. *Eur Heart J* 2005;26:2368–2374.
 52. Niebauer J, Volk HD, Kemp M, Dominguez M, Schumann RR, Rauchhaus M, Poole-Wilson PA, Coats AJ, Anker SD. Endotoxin and immune activation in chronic heart failure: a prospective cohort study. *Lancet* 1999;353:1838–1842.
 53. Hoeper MM, Galie N, Murali S, Olschewski H, Rubenfire M, Robbins IM, Farber HW, McLaughlin V, Shapiro S, Pepke-Zaba J, *et al.* Outcome after cardiopulmonary resuscitation in patients with pulmonary arterial hypertension. *Am J Respir Crit Care Med* 2002;165: 341–344.
 54. Tongers J, Schwerdtfeger B, Klein G, Kempf T, Schaefer A, Knapp JM, Niehaus M, Korte T, Hoeper MM. Incidence and clinical relevance of supraventricular tachyarrhythmias in pulmonary hypertension. *Am Heart J* 2007;153:127–132.
 55. Goldstein JA, Harada A, Yagi Y, Barzilai B, Cox JL. Hemodynamic importance of systolic ventricular interaction, augmented right atrial contractility and atrioventricular synchrony in acute right ventricular dysfunction. *J Am Coll Cardiol* 1990;16:181–189.
 56. Adhyapak SM, Pujar SV, Mahala BK, Shetty PK. Echocardiographic evaluation of the morphology and function of the right ventricle in Eisenmenger’s syndrome and idiopathic pulmonary hypertension. *Indian Heart J* 2006;58:341–344.
 57. Ghio S, Klersy C, Magrini G, D’Armini AM, Scelsi L, Raineri C, Pasotti M, Serio A, Campana C, Vigano M. Prognostic relevance of the echocardiographic assessment of right ventricular function in patients with idiopathic pulmonary arterial hypertension. *Int J Cardiol* 2010;140:272–278.
 58. Vonk MC, Sander MH, van den Hoogen FH, van Riel PL, Verheugt FW, van Dijk AP. Right ventricle Tei-index: a tool to increase the accuracy of non-invasive detection of pulmonary arterial hypertension in connective tissue diseases. *Eur J Echocardiogr* 2007;8: 317–321.
 59. Lopez-Candales A, Bazaz R, Edelman K, Gulyasy B. Apical systolic eccentricity index: a better marker of right ventricular compromise in pulmonary hypertension. *Echocardiography* 2010;27:534–538.
 60. Boissiere J, Gautier M, Machet MC, Hanton G, Bonnet P, Eder V. Doppler tissue imaging in assessment of pulmonary hypertension-induced right ventricle dysfunction. *Am J Physiol Heart Circ Physiol* 2005;289:H2450–H2455.
 61. Menzel T, Kramm T, Bruckner A, Mohr-Kahaly S, Mayer E, Meyer J. Quantitative assessment of right ventricular volumes in severe chronic thromboembolic pulmonary hypertension using transthoracic three-dimensional echocardiography: changes due to pulmonary thromboendarterectomy. *Eur J Echocardiogr* 2002;3:67–72.
 62. Rajagopalan N, Simon MA, Shah H, Mathier MA, Lopez-Candales A. Utility of right ventricular tissue Doppler imaging: correlation with right heart catheterization. *Echocardiography* 2008;25:706–711.
 63. Harvey S, Harrison DA, Singer M, Ashcroft J, Jones CM, Elbourne D, Brampton W, Williams D, Young D, Rowan K. Assessment of the clinical effectiveness of pulmonary artery catheters in management of patients in intensive care (PAC-Man): a randomised controlled trial. *Lancet* 2005;366:472–477.
 64. Sandham JD, Hull RD, Brant RF, Knox L, Pineo GF, Doig CJ, Laporta DP, Viner S, Passerini L, Devitt H, *et al.* A randomized, controlled trial of the use of pulmonary-artery catheters in high-risk surgical patients. *N Engl J Med* 2003;348:5–14.
 65. Mercat A, Diehl JL, Meyer G, Teboul JL, Sors H. Hemodynamic effects of fluid loading in acute massive pulmonary embolism. *Crit Care Med* 1999;27:540–544.
 66. Buckley MS, Feldman JP. Nebulized milrinone use in a pulmonary hypertensive crisis. *Pharmacotherapy* 2007;27:1763–1766.
 67. Sablotzki A, Starzmann W, Scheubel R, Grond S, Czeslick EG. Selective pulmonary vasodilation with inhaled aerosolized milrinone in heart transplant candidates. *Can J Anaesth* 2005;52:1076–1082.
 68. Angle MR, Molloy DW, Penner B, Jones D, Prewitt RM. The cardiopulmonary and renal hemodynamic effects of norepinephrine in canine pulmonary embolism. *Chest* 1989;95:1333–1337.
 69. Kerbaul F, Rondelet B, Motte S, Fesler P, Hubloue I, Ewalenko P, Naeije R, Brimiouille S. Effects of norepinephrine and dobutamine on pressure load-induced right ventricular failure. *Crit Care Med* 2004;32:1035–1040.
 70. Braun EB, Palin CA, Hogue CW. Vasopressin during spinal anesthesia in a patient with primary pulmonary hypertension treated with intravenous epoprostenol. *Anesth Analg* 2004;99:36–37.
 71. Price LC, Forrest P, Sodhi V, Adamson DL, Nelson-Piercy C, Lucey M, Howard LS. Use of vasopressin after caesarean section in idiopathic pulmonary arterial hypertension. *Br J Anaesth* 2007;99:552–555.
 72. Tayama E, Ueda T, Shojima T, Akasu K, Oda T, Fukunaga S, Akashi H, Aoyagi S. Arginine vasopressin is an ideal drug after cardiac surgery for the management of low systemic vascular resistant hypotension concomitant with pulmonary hypertension. *Interact Cardiovasc Thorac Surg* 2007;6:715–719.
 73. Kerbaul F, Rondelet B, Demester JP, Fesler P, Huez S, Naeije R, Brimiouille S. Effects of levosimendan versus dobutamine on pressure load-induced right ventricular failure. *Crit Care Med* 2006;34: 2814–2819.
 74. Kleber FX, Bollmann T, Borst MM, Costard-Jackle A, Ewert R, Kivikko M, Petterson T, Pohjanjousi P, Sonntag S, Wikstrom G. Repetitive dosing of intravenous levosimendan improves pulmonary hemodynamics in patients with pulmonary hypertension: results of a pilot study. *J Clin Pharmacol* 2009;49:109–115.
 75. Kerbaul F, Gariboldi V, Giorgi R, Mekkaoui C, Guieu R, Fesler P, Gouin F, Brimiouille S, Collart F. Effects of levosimendan on acute pulmonary embolism-induced right ventricular failure. *Crit Care Med* 2007;35:1948–1954.
 76. Missant C, Rex S, Segers P, Wouters PF. Levosimendan improves right ventriculo-vascular coupling in a porcine model of right ventricular dysfunction. *Crit Care Med* 2007;35:707–715.
 77. Morelli A, Teboul JL, Maggiore SM, Vieillard-Baron A, Rocco M, Conti G, De Gaetano A, Picchini U, Orecchioni A, Carbone I, *et al.* Effects of levosimendan on right ventricular afterload in patients with acute respiratory distress syndrome: a pilot study. *Crit Care Med* 2006;34:2287–2293.
 78. Yontar OC, Yalta K, Yilmaz MB. Superiority of levosimendan over dobutamine in right ventricle failure. *Crit Care Med* 2010;38:342–343, author reply 343–344.
 79. Ruiter G, Lankhorst S, Boonstra A, Postmus PE, Zwegman S, Westerhof N, van der Laarse WJ, Vonk-Noordegraaf A. Iron deficiency is common in idiopathic pulmonary arterial hypertension. *Eur Respir J* 2011;37:1386–1391.
 80. Myles PS, Hall JL, Berry CB, Esmore DS. Primary pulmonary hypertension: prolonged cardiac arrest and successful resuscitation

- following induction of anesthesia for heart-lung transplantation. *J Cardiothorac Vasc Anesth* 1994;8:678–681.
81. Gordon C, Collard CD, Pan W. Intraoperative management of pulmonary hypertension and associated right heart failure. *Curr Opin Anaesthesiol* 2010;23:49–56.
82. Pritts CD, Pearl RG. Anaesthesia for patients with pulmonary hypertension. *Curr Opin Anaesthesiol* 2010;23:6.
83. Viitanen A, Salmenpera M, Heinonen J. Right ventricular response to hypercarbia after cardiac surgery. *Anesthesiology* 1990;73:393–400.
84. Viitanen A, Salmenpera M, Heinonen J, Hynynen M. Pulmonary vascular resistance before and after cardiopulmonary bypass: the effect of PaCO₂. *Chest* 1989;95:773–778.
85. Aqel RA, Aljaroudi W, Hage FG, Tallaj J, Rayburn B, Nanda NC. Left ventricular collapse secondary to pericardial effusion treated with pericardicentesis and percutaneous pericardiotomy in severe pulmonary hypertension. *Echocardiography* 2008;25:658–661.
86. Dunne JV, Chou JP, Viswanathan M, Wilcox P, Huang SH. Cardiac tamponade and large pericardial effusions in systemic sclerosis: a report of four cases and a review of the literature. *Clin Rheumatol* 2011;30:433–438.
87. Hemnes AR, Gaine SP, Wiener CM. Poor outcomes associated with drainage of pericardial effusions in patients with pulmonary arterial hypertension. *South Med J* 2008;101:490–494.
88. Kerstein D, Levy PS, Hsu DT, Hordof AJ, Gersony WM, Barst RJ. Blade balloon atrial septostomy in patients with severe primary pulmonary hypertension. *Circulation* 1995;91:2028–2035.
89. Sandoval J, Gaspar J, Pena H, Santos LE, Cordova J, Del Valle K, Rodriguez A, Pulido T. Effect of atrial septostomy on the survival of patients with severe pulmonary arterial hypertension. *Eur Respir J* (In press)
90. D'Armini AM, Zanotti G, Ghio S, Magrini G, Pozzi M, Scelsi L, Meloni G, Klersy C, Vigano M. Reverse right ventricular remodeling after pulmonary endarterectomy. *J Thorac Cardiovasc Surg* 2007;133:162–168.
91. Kramer MR, Valantine HA, Marshall SE, Starnes VA, Theodore J. Recovery of the right ventricle after single-lung transplantation in pulmonary hypertension. *Am J Cardiol* 1994;73:494–500.
92. Reesink HJ, Marcus JT, Tulevski II, Jamieson S, Kloek JJ, Vonk Noordegraaf A, Bresser P. Reverse right ventricular remodeling after pulmonary endarterectomy in patients with chronic thromboembolic pulmonary hypertension: utility of magnetic resonance imaging to demonstrate restoration of the right ventricle. *J Thorac Cardiovasc Surg* 2007;133:58–64.
93. Rensing BJ, McDougall JC, Breen JF, Vigneswaran WT, McGregor CG, Rumberger JA. Right and left ventricular remodeling after orthotopic single lung transplantation for end-stage emphysema. *J Heart Lung Transplant* 1997;16:926–933.
94. Olschewski H, Ghofrani HA, Schmehl T, Winkler J, Wilkens H, Hoper MM, Behr J, Kleber FX, Seeger W; German PPH Study Group. Inhaled iloprost to treat severe pulmonary hypertension: an uncontrolled trial. *Ann Intern Med* 2000;132:435–443.
95. Hoeper MM, Olschewski H, Ghofrani HA, Wilkens H, Winkler J, Borst MM, Niedermeyer J, Fabel H, Seeger W; German PPH Study Group. A comparison of the acute hemodynamic effects of inhaled nitric oxide and aerosolized iloprost in primary pulmonary hypertension. *J Am Coll Cardiol* 2000;35:176–182.
96. Bhorade S, Christenson J, O'Connor M, Lavoie A, Pohlman A, Hall JB. Response to inhaled nitric oxide in patients with acute right heart syndrome. *Am J Respir Crit Care Med* 1999;159:571–579.
97. Della Rocca G, Coccia C, Pompei L, Costa MG, Di Marco P, Pietropaoli P. Inhaled aerosolized prostaglandin E₁, pulmonary hemodynamics, and oxygenation during lung transplantation. *Minerva Anestesiol* 2008;74:627–633.
98. Della Rocca G, Coccia C. Nitric oxide in thoracic surgery. *Minerva Anestesiol* 2005;71:313–318.
99. George I, Xydias S, Topkara VK, Ferdinando C, Barnwell EC, Gableman L, Sladen RN, Naka Y, Oz MC. Clinical indication for use and outcomes after inhaled nitric oxide therapy. *Ann Thorac Surg* 2006;82:2161–2169.
100. Vachieri JL, Huez S, Gillies H, Layton G, Hayashi N, Gao X, Naeije R. Safety, tolerability and pharmacokinetics of an intravenous bolus of sildenafil in patients with pulmonary arterial hypertension. *Br J Clin Pharmacol* 2011;71:289–292.
101. Jais X, Launay D, Yaici A, Le Pavec J, Tcherakian C, Sitbon O, Simonneau G, Humbert M. Immunosuppressive therapy in lupus- and mixed connective tissue disease-associated pulmonary arterial hypertension: a retrospective analysis of twenty-three cases. *Arthritis Rheum* 2008;58:521–531.
102. Lewis GD, Shah R, Shahzad K, Camuso JM, Pappagianopoulos PP, Hung J, Tawakol A, Gerszten RE, Systrom DM, Bloch KD, et al. Sildenafil improves exercise capacity and quality of life in patients with systolic heart failure and secondary pulmonary hypertension. *Circulation* 2007;116:1555–1562.
103. Mehta S, Helmersen D, Provencher S, Hirani N, Rubens FD, De Perrot M, Blostein M, Boutet K, Chandy G, Dennie C, et al. Diagnostic evaluation and management of chronic thromboembolic pulmonary hypertension: a clinical practice guideline. *Can Respir J* 2010;17:301–334.
104. Montani D, O'Callaghan DS, Savale L, Jais X, Yaici A, Maitre S, Dorfmueller P, Sitbon O, Simonneau G, Humbert M. Pulmonary veno-occlusive disease: recent progress and current challenges. *Respir Med* 2010;104:S23–S32.
105. Palazzini M, Manes A. Pulmonary veno-occlusive disease misdiagnosed as idiopathic pulmonary arterial hypertension. *Eur Respir Rev* 2009;18:177–180.
106. Detsky ME, Balter MS, Sridhar SK, Granton J. Clinical problem-solving: under pressure. *N Engl J Med* 2010;362:449–454.
107. Montani D, Jais X, Dorfmueller P, Simonneau G, Sitbon O, Humbert M. Goal-oriented therapy in pulmonary veno-occlusive disease: a word of caution. *Eur Respir J* 2009;34:1204–1206.
108. Christie JD, Edwards LB, Kucheryavaya AY, Aurora P, Dobbels F, Kirk R, Rahmel AO, Stehlik J, Hertz MI. The Registry of the International Society for Heart and Lung Transplantation: twenty-seventh official adult lung and heart-lung transplant report—2010. *J Heart Lung Transplant* 2010;29:1104–1118.
109. Orens JB, Estenne M, Arcasoy S, Conte JV, Corris P, Egan JJ, Egan T, Keshavjee S, Knoop C, Kotloff R, et al. International guidelines for the selection of lung transplant candidates: 2006 update—a consensus report from the pulmonary scientific council of the International Society for Heart and Lung Transplantation. *J Heart Lung Transplant* 2006;25:745–755.
110. Fischer S, Hoeper MM, Tomaszek S, Simon A, Gottlieb J, Welte T, Haverich A, Strueber M. Bridge to lung transplantation with the extracorporeal membrane ventilator Novalung in the venovenous mode: the initial Hannover experience. *ASAIO J* 2007;53:168–170.
111. Fischer S, Simon AR, Welte T, Hoeper MM, Meyer A, Tessmann R, Gohrbandt B, Gottlieb J, Haverich A, Strueber M. Bridge to lung transplantation with the novel pumpless interventional lung assist device Novalung. *J Thorac Cardiovasc Surg* 2006;131:719–723.
112. Olsson KM, Simon A, Strueber M, Hadem J, Wiesner O, Gottlieb J, Fuehner T, Fischer S, Warnecke G, Kuhn C, et al. Extracorporeal membrane oxygenation in nonintubated patients as bridge to lung transplantation. *Am J Transplant* 2010;10:2173–2178.
113. Strueber M, Hoeper MM, Fischer S, Cypel M, Warnecke G, Gottlieb J, Pierre A, Welte T, Haverich A, Simon AR, et al. Bridge to thoracic organ transplantation in patients with pulmonary arterial hypertension using a pumpless lung assist device. *Am J Transplant* 2009;9:853–857.
114. Schmid C, Philipp A, Hilker M, Arlt M, Trabold B, Pfeiffer M, Schmid FX. Bridge to lung transplantation through a pulmonary artery to left atrial oxygenator circuit. *Ann Thorac Surg* 2008;85:1202–1205.
115. Bein T, Weber F, Philipp A, Prasser C, Pfeifer M, Schmid FX, Butz B, Birnbaum D, Taeger K, Schlitt HJ. A new pumpless extracorporeal interventional lung assist in critical hypoxemia/hypercapnia. *Crit Care Med* 2006;34:1372–1377.
116. Satoh H, Masuda Y, Izuta S, Yaku H, Obara H. Pregnant patient with primary pulmonary hypertension: general anesthesia and extracorporeal membrane oxygenation support for termination of pregnancy. *Anesthesiology* 2002;97:1638–1640.
117. Erzurum S, Rounds SI, Stevens T, Aldred M, Aliotta J, Archer SL, Asosingh K, Balaban R, Bauer N, Bhattacharya J, et al. Strategic plan for lung vascular research: an NHLBI-ORDR workshop report. *Am J Respir Crit Care Med* 2010;182:1554–1562.