Advances in diagnosis and treatment of pulmonary arterial hypertension in neonates and children with congenital heart disease

Monnipa Suesaowalak, John P Cleary, Anthony C Chang
Orange, California, USA

Background: **This article aims to review recent advances in the diagnosis and treatment of pulmonary arterial hypertension in neonates and children with congenital heart disease.**

Data sources: **Articles on pulmonary arterial hypertension in congenital heart disease were retrieved from PubMed and MEDLINE published after 1958.**

Results: **A diagnosis of primary (or idiopathic) pulmonary arterial hypertension is made when no known risk factor is identified. Pulmonary arterial hypertension associated with congenital heart disease constitutes a heterogenous group of conditions and has been characterized by congenital systemic-to-pulmonary shunts. Despite the similarities in histologic appearance of pulmonary vascular disease, there are differences between pulmonary arterial hypertension secondary to congenital systemic-to-pulmonary shunts and those with other conditions with respect to pathophysiology, therapeutic strategies, and prognosis. Revision and subclassification within the category of secondary pulmonary arterial hypertension based on pathophysiology were conducted to improve specific treatments. The timing of surgical repair is crucial to prevent and minimize risk of postoperative pulmonary arterial hypertension. Drug therapies including prostacyclin, endothelin-receptor antagonist, phosphodiesterase inhibitor, and nitric oxide have been evolved with promising results in neonates and children.**

Conclusions: **Among the different forms of congenital heart diseases, an early correction generally prevents subsequent development of pulmonary arterial hypertension. Emerging therapies for treatment of patients with idiopathic pulmonary arterial hypertension also improve quality of life and survival in neonates and children with congenital heart disease associated with pulmonary arterial hypertension. Heart and lung transplantation or lung transplantation in combination with repair of the underlying cardiac defect is a therapeutic option in a minority of patients. Partial repair options are also beneficial in some selected cases. Randomized controlled trials are needed to evaluate the safety and efficacy of these therapies including survival and long-term outcome.**

World J Pediatr 2010;6(1):13-31

Key words: **children;**
congenital heart disease;
endothelin-receptor antagonist;
neonate;
nitric oxide;
phosphodiesterase inhibitor;
prostacyclin;
pulmonary arterial hypertension

Author Affiliations: Pediatric Cardiac Surgery Foundation, Bangkok, Thailand (Suesaowalak M); CHOC Pediatric Subspecialty Faculty, Children's Hospital of Orange County, Orange, California, USA (Cleary JP); CHOC Heart Institute, Children's Hospital of Orange County, Orange, California, USA (Chang AC)

Corresponding Author: Anthony C Chang, MD, MBA, MPH, CHOC Heart Institute, Children's Hospital of Orange County, 455 S. Main Street, Orange, CA 92868, USA (Tel: +1-714-532-7576; Fax: +1-714-289-4962; Email: achang@choc.org)

doi:10.1007/s12519-010-0002-9
©2010, World J Pediatr. All rights reserved.

Introduction

Pulmonary arterial hypertension (PAH) is a known sequela of congenital heart disease (CHD). PAH results in increased morbidity and mortality. Recent advances in understanding of pathogenesis and pathophysiology have led to improvements in diagnosis and management strategies. The goals of therapy are to improve quality of life, functional class, exercise capacity, pulmonary hemodynamics, and long-term survival for children with CHD associated with PAH.[1]

Idiopathic pulmonary arterial hypertension (iPAH) is defined as a mean pulmonary artery pressure of more than 25 mmHg at rest or more than 30 mmHg during exercise, with a normal pulmonary artery wedge pressure, and an increased pulmonary vascular resistance

of more than 3 Wood units, and the absence of related or associated condition.[2-4] This hemodynamic definition is also applied to PAH secondary to CHD in children and adults.[5,6] However, most pediatricians would accept that PAH is the systolic pulmonary artery pressure of more than 50% of systemic blood pressure.[7] Exercise hemodynamics is important for the diagnosis of PAH in children. Children with PAH may have normal-high pulmonary artery pressure and often have an exaggerated response of the pulmonary vascular bed to exercise as well as in response to hypoventilation compared with adults.[4,5] The pulmonary artery wedge pressure is normal unless there are left heart diseases, such as mitral stenosis, mitral regurgitation, or left ventricular dysfunction causing pulmonary venous hypertension.

Classification

Because the pulmonary artery pressure results from the pulmonary blood flow time pulmonary vascular resistance, either increase in pulmonary blood flow (hyperkinetic) or pulmonary vascular resistance (pulmonary vascular obstruction or pulmonary venous hypertension) can cause PAH (Table 1).[1] Patients with CHD and PAH may have reversible vasoconstriction and/or irreversible obstruction of the pulmonary vasculature or both. In 1998, a clinical classification of pulmonary hypertension (the Evian classification) was proposed. PAH related to congenital systemic-to-pulmonary shunts was classified in group 1. At the Third World Symposium held in 2003, this classification was revised.[8] Because of different forms of CHD resulting in PAH, the guidelines for classification of congenital systemic-to-pulmonary shunts were drafted at the same time. Subcategories of CHD based on anatomy (defects above and below the tricuspid valve and specific type of complex diseases), size of shunt defects, hemodynamic restriction of shunt, direction of shunt, associated extracardiac abnormalities, and status of anatomic repair were proposed by Galiè in 2006 (Table 2).[9]

Recently van Albada and Berger[10] proposed some details of classification, such as surgical shunt, pulmonary arterial banding, and associated cardiac anomalies that were recognized to be risk factors for PAH development. From pediatric cardiology point of view, these can be classified into 7 groups of congenitally malformed hearts based on circulatory pathophysiology, which determine clinical course, possibility of treatment, and prognosis (Table 3):[11] significant shunting lesion, iPAH-like physiology, PAH due to past or present pulmonary venous hypertension, Eisenmenger physiology, Fontan-like physiology, unilateral PAH, and hypoplastic pulmonary artery system.

During the Fourth World Symposium on Pulmonary Hypertension held in Dana Point, California in 2008, pulmonary hypertension reclassification was proposed based on clinical evolution, histopathology, and response to therapy. Systemic-to-pulmonary artery shunts were classified in group 1 while CHD other than left-to-right

Table 1. Classification of pulmonary arterial hypertension

Type	Classification
Hyperkinetic	$P = r \times F$
Pulmonary vascular obstruction or pulmonary venous hypertension	$P = R \times f$

P: increased pulmonary artery pressure; F: high pulmonary blood flow; f: normal pulmonary blood flow; *R*: high total pulmonary resistance; r: normal total pulmonary resistance. (Adapted from Barst[1] with permission)

Table 2. Proposed revised classification of congenital systemic-to-pulmonary shunts associated with pulmonary arterial hypertension

1 Type
- 1.1 Simple pre-tricuspid shunts
  - 1.1.1 Atrial septal defect
    - 1.1.1.1 Ostium secundum
    - 1.1.1.2 Sinus venosus
  - 1.1.2 Total or partial unobstructed anomalous pulmonary venous return
- 1.2 Simple post-tricuspid shunts
  - 1.2.1 Ventricular septal defect
  - 1.2.2 Patent ductus arteriosus
- 1.3 Combined shunts (describe combination and define predominant defect)
- 1.4 Complex CHD
  - 1.4.1 Atrioventricular septal defects
    - 1.4.1.1 Partial (ostium primum atrial septal defect)
    - 1.4.1.2 Complete
  - 1.4.2 Truncus arteriosus
  - 1.4.3 Single ventricle physiology with unobstructed pulmonary blood flow
  - 1.4.4 Transposition of the great arteries with ventricular septal defect (without pulmonary stenosis) and/or patent ductus arteriosus
  - 1.4.5 Others

2 Dimensions (specify for each defect if more than one congenital heart defect)
- 2.1 Hemodynamic
  - 2.1.1 Restrictive (pressure gradient across the defect)
  - 2.1.2 Nonrestrictive
- 2.2 Anatomic
  - 2.2.1 Small to moderate (atrial septal defect ≤2.0 cm and ventricular septal defect ≤1.0 cm)
  - 2.2.2 Large (atrial septal defect >2.0 cm and ventricular septal defect >1.0 cm)

3 Direction of shunt
- 3.1 Predominantly systemic-to-pulmonary
- 3.2 Predominantly pulmonary-to-systemic
- 3.3 Bidirectional

4 Associated extracardiac abnormalities

5 Repair status
- 5.1 Unoperated
- 5.2 Palliated (specify type of operation (s), age at surgery)
- 5.3 Repaired (specify type of operation (s), age at surgery)

Adapted from Galie[9] with permission.

shunts was classified in group 5. In addition, hemodynamic data (pulmonary-to-systemic flow ratio, Qp:Qs) were used to classify shunts. The dimension of the shunts measured by two-dimensional echocardiography was not reliable in this proposed reclassification (Robbins IM, Simonneau G, unpublished data).

Pathophysiology

The classification of the 7 groups of PAH in children with CHD was based on circulatory pathophysiology.[10,11]

Significant shunting lesion

The postnatal change of pulmonary circulation results in rapidly decreased pulmonary vascular resistance and usually falls to reach adult level after 2 to 8 weeks of age. In the presence of large systemic-to-pulmonary artery communication, pulmonary overcirculation ensues, resulting in clinical manifestations of congestive heart failure during infancy. Increased shear stress and the excess flow through the pulmonary vascular bed lead to the development of pulmonary vascular disease and an increase in pulmonary vascular resistance. With time, pulmonary artery pressure increases, and the degree of left-to-right shunt decreases with improvement of heart failure symptoms. Chronic exposure of the pulmonary vasculature to increased pulmonary blood flow produces endothelial cell damage as well as release and activation of factors involving in vasoconstriction and structural change. When pulmonary artery pressure reaches systemic levels, there is reversal of the direction of left-to-right shunt, resulting in hypoxemia and cyanosis so-called Eisenmenger syndrome.

In 1958, Heath and Edwards[12] suggested a progression of structural changes (grade I through grade VI) in the histology of lung biopsy. Pulmonary vascular lesions begin with medial hypertrophy in the small pulmonary arteries,[13] followed by cellular intimal proliferation and thickening, and intimal fibrosis, leading to lumen occlusion. With advancement of diseases, progressively generalized dilatation of the muscular arteries (plexiform lesions), as well as thinning and fibrosis of the media are superimposed on the formation of numerous complex dilatation lesions, and necrotizing arteritis takes place. This classification has several drawbacks. The more severe Heath-Edwards changes (grade IV and higher) are unusual in the first 2 years of life, even in the presence of severely elevated pulmonary vascular resistance. The advanced changes, if present, are often irregularly distributed throughout the lung.

In 1978, Robinovitch et al[14,15] developed a quantitative method for analysis of the pulmonary vascular bed in infants and young children. Structural findings of increased muscularization and impaired growth of the pulmonary arteries were assessed morphometrically and graded (Table 4 and Fig. 1).

Some specific CHDs are known to be of high risk for PAH development if left untreated.[16-19] Complex CHDs, such as truncus arteriosus, transposition of the great arteries, and complete atrioventricular canal defect (Table 2) carry the highest risk for the development of severe pulmonary vascular disease in the first year of life. Simple post-tricuspid shunts including ventricular septal defect and patent ductus arteriosus are prone to develop severe PAH compared to pre-tricuspid shunt, and atrial

Table 3. New proposed classification of pulmonary arterial hypertension in the setting of congenitally malformed hearts as based on circulatory pathophysiology

Significant shunting lesions	iPAH-like physiology	PAH due to past or present PVH	Eisenmenger physiology	Fontan-like physiology	Unilateral PAH	Hypoplastic PA system
a) for corrective surgery, PVR is low and presents no problem b) for corrective surgery, PVR elevated, risk increased but accepted c) for corrective surgery, PVR elevated, risk too high, not operable	a) small unoperated lesion (e.g., PFO, ASD, VSD, PDA) not hemodynamically related to PAH b) small residua after corrective surgery of a shunting lesion, not hemodynamically related to PAH	a) after corrective surgery of pulmonary venous stenosis or aortic/mitral valvar disease or coarctation, with normal wedge pressure and left ventricular function b) PAH due to left ventricular dysfunction with abnormal wedge pressure and increased PVR	a) classical Eisenmenger physiology: no sub-pulmonary outflow obstruction; predominantly right-to-left shunting at atrial, ventricular or arterial level, no intraventricular mixing b) functionally univentricular physiology: no sub-pulmonary outflow obstruction; systemic desaturation is due to intraventricular mixing	a) after Fontan operation with the right atrium being incorporated b) Fontan with a lateral or extracardiac conduit, right atrium excluded, no fenestration c) anatomy as above under b), with fenestration	a) due to a surgical shunt previously created to increase pulmonary blood flow which has led to significant PAH on that side b) due to congenital origin of one pulmonary artery or of major collateral vessels from the aorta, causing PAH	a) after corrective surgery of tetralogy of Fallot without major anatomical obstructions of the pulmonary vascular system, and PAH b) after corrective surgery of pulmonary atresia without major anatomical obstructions of the pulmonary vascular system, and PAH

ASD: atrial septal defect; iPAH: idiopathic pulmonary arterial hypertension; PA system: pulmonary vascular system; PDA: patent ductus arteriosus; PFO: patent foramen ovale; PVH: pulmonary venous hypertension; PVR: pulmonary vascular resistance; VSD: ventricular septal defect. (Adapted from Schulze-Neick et al[11] with permission)

septal defect which usually increased pulmonary vascular resistance from the third decade of life.

In most instances, the congenital systemic-to-pulmonary artery shunts are reversible if detected early.[15,19] In the past, lung biopsy and assessment of arteriopathy were an aid to identify the feasibility of surgery and reversibility of PAH secondary to CHD.[20-23] In 280 autopsy studies in infants under one year of age with CHD, advanced pulmonary hypertensive arteriopathy (grade IV or more) was rarely found.[24]

Whether pulmonary artery pressure and pulmonary vascular resistance eventually return to normal or remain elevated after surgical repair is determined by the morphometric and the Heath-Edwards grades as well as the age of the patient at the time of surgical repair. Robinovitch et al[15] studied the correlation between lung biopsy at the time of surgical repair and postoperative pulmonary hemodynamic findings in 74 patients with congenital heart defects frequently complicated by PAH, such as ventricular septal defect, D-transposition of the great arteries, and complete atrioventricular canal defect. One year after repair, pulmonary artery pressure and/or pulmonary vascular resistance was normal in all patients whose conditions were corrected surgically before 9 months of age regardless of the severity of pulmonary vascular changes. The pulmonary artery pressure and pulmonary vascular resistance were increased in all patients whose conditions were repaired after 2 years of age with grade C morphometric findings or increased to a severe degree if associated with Heath-Edwards grade III.

iPAH-like physiology

PAH associated with small unoperated lesions (patent foramen ovale, atrial septal defect, ventricular septal defect, and patent ductus arteriosus) or hemodynamically insignificant residua after corrective surgery of a shunt lesion is thought to be the combination of iPAH and a small CHD. This group of patients are thought to have some genetic predisposition to develop PAH even in low flow and low pressure shunt lesions. There is evidence showing mutations in receptors in the TGF-β superfamily, which affect vascular intimal proliferation and are responsible for almost all familial PAH.[25] These mutations are usually in BMPR2 (bone morphogenetic protein receptor 2)[26] and in *ALK-1* (activin-like kinase 1: the receptor involved in hereditary hemorrhagic telangiectasia). Other important signaling systems including K channels,[27] serotonin, angiopoietin, and cyclooxygenase have been found to be involved in PAH.[28] It is unlikely that one factor or gene mutation will explain all forms and cases of PAH.

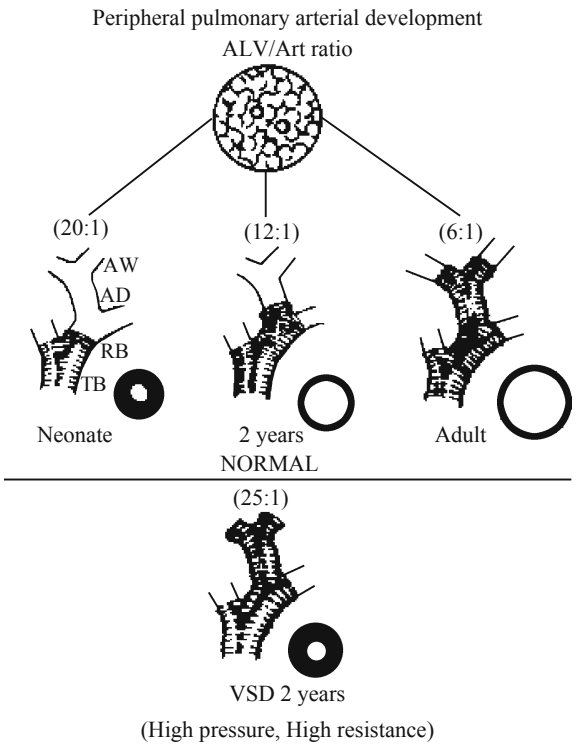

Fig. 1. A summary of schema showing morphometric changes of extension of muscle into peripheral arteries, percent wall thickness and artery number (alveolar arterial ratio (ALV/Art)) as they relate to age. Above panel is normal development. Bottom shows abnormalities in all three features in the 2-year-old child with a hypertensive ventricular septal defect (VSD). TB: artery accompanying a terminal bronchiolus; RB: artery accompanying a respiratory bronchiolus; AD: artery accompanying an alveolar duct; AW: artery accompanying an alveolar wall. (Adapted from Rabinovitch et al[14] with permission)

Table 4. Lung biopsy in congenital heart disease: a morphometric approach to pulmonary vascular disease

Grade	Lung biopsy findings
A	Extension of muscle into peripheral arteries normally nonmuscular, either as a solitary finding or associated with a mild increase in the medial wall thickness of the normally muscular arteries (≤1.5 times normal)
B	Extension as in grade A but greater medial hypertrophy
	Mild: Medial wall thickness is greater than 1.5 but less than 2 times normal
	Severe: Medial wall thickness is 2 times normal or greater
C	Feature of B (severe), with a decreased number of peripheral arteries relative to alveoli and usually decreased arterial size
	Mild: More than half of the normal number of arteries is present
	Severe: Half of the normal number of arteries or less is observed

Adapted from Rabinovitch et al[15] with permission.

PAH due to past or present pulmonary venous hypertension

This category consists of left-sided valvular heart diseases, pulmonary venous stenosis, total anomalous pulmonary venous drainage with obstruction, cor triatriatum, hypoplastic left heart syndrome with a restrictive atrial septal defect, left-sided atrial or ventricular heart diseases, and coarctation of the aorta. With the same elevation of pulmonary venous pressure, the pulmonary artery pressure may vary from one child to another because of the degree of pulmonary arteriolar vasoreactivity.[1] This category requires therapies directed at relieving valvular mechanical defects or improving myocardial performance rather than pulmonary vasodilator therapy. PAH associated with pulmonary venous hypertension caused by pulmonary venous stenosis or left-sided heart obstruction can be reversible after corrective surgery. However, some patients develop a reaction to pulmonary venous hypertension, either after corrective surgery or an ongoing problem (e.g., left ventricular myocardial diseases with increased end diastolic pressures).

Eisenmenger physiology

Eisenmenger physiology tends to be recognized in the middle of the second decade of life. Multisystem involvement complicated in Eisenmenger syndrome has long been recognized including cerebrovascular accidents (stroke or transient ischemic attack), bleeding, thrombotic diathesis, infections, hepatic and renal involvement, progressive right ventricular failure, cardiac arrhythmia, and sudden cardiac death.[29]

Classical Eisenmenger physiology includes cyanosis from predominant right-to-left shunt through atrial, ventricular, or great arteries communications. In Eisenmenger patients, cyanosis may present with exercise and become cyanotic at rest as diseases progress. Some patients may exhibit differential cyanosis with right-to-left shunt through great arteries communication via the patent ductus arteriosus. Clubbing is invariable in Eisenmenger patients, while it typically is not a feature of iPAH.[5,30]

Hematological abnormalities consist of secondary erythrocytosis which is a physiologic response to chronic hypoxemia. Erythrocytosis increases only the red blood cells to improve oxygen delivery. Thrombocytopenia also contributes to a bleeding diathesis after surgical and dental procedures. Abnormal hemostasis is of particular interest in Eisenmenger patients with both bleeding and thrombotic diathesis. Thrombus in proximal pulmonary arteries, pulmonary infarction, and hemoptysis are common in adult patients with Eisenmenger physiology.

Cerebral complications including stroke and cerebral abscess have been found to influence the quality of life of patients.[31] Endocarditis may complicate outcome.[31] Renal dysfunction, hyperuricemia, clinical gout, cholelithiasis, and cholecystitis may ensue secondary to high erythrocyte turnover. Progressive right ventricular failure and cardiac arrhythmia are frequent late sequelaes in patients with Eisenmenger physiology.

Fontan-like physiology

In contrast to a 2-ventricle circulation, lesions of univentricular physiology with surgical creation of cavopulmonary anastomosis (Glenn shunt and its variants or Fontan palliation and its variants) are very fragile. With Glenn shunt, the superior vena cava connects directly with the pulmonary arteries while the inferior vena cava and the superior vena cava both connect to the pulmonary arteries in the Fontan anastomosis. Because cardiac output is determined by transpulmonary flow (itself mainly determined by pulmonary vascular resistance), the lowest possible pulmonary vascular resistance is critical to the maintenance of cardiac output. Cardiac output can be increased by improving flow to the lungs (stream line non-obstructive Fontan connection, stenting of hypoplastic or stenotic pulmonary artery) or by bypassing the lungs with a fenestration.[32] In these patients, the increase in pulmonary vascular resistance leads ultimately to failure of the circulation.

Unilateral PAH

Shunts created by unilateral surgery for increasing pulmonary blood flow (Blalock-Taussig, Waterston, and Pott) in congenital cyanotic heart lesions with decreased pulmonary blood flow cause PAH in the corresponding lung. The large unrestrictive congenital aortopulmonary collaterals (major aortopulmonary collateral arteries or MAPCAs) may result in high degree of pulmonary blood flow to the affected lung and segmental PAH. Differential lung perfusion in congenital unilateral pulmonary artery stenosis and pulmonary hyperperfusion of the contralateral lung is another cause of unilateral PAH.

The anomalous origin of one pulmonary artery from the ascending aorta with 2 normal semilunar valves (so-called "hemitruncus") results in increased pulmonary blood flow to the affected lung and unilateral PAH. Interestingly, some patients with anomalous origin of one pulmonary artery from the ascending aorta have elevated pulmonary vascular resistance in the contralateral lung. The reasons are not yet well understood. The proposed mechanisms are neurovascular reflexes or humoral vasoactive mediators, or both. Without surgical correction in the first year of life, PAH may develop in both lungs.[33]

Hypoplastic pulmonary artery system

In CHDs with decreased pulmonary blood flow, such

as Tetralogy of Fallot or pulmonary atresia and intact ventricular septum, hypoplasia of the pulmonary arterial musculature is observed.[34] In addition, thromboemboli can attribute to high hematocrits as well. After corrective surgery for Tetralogy of Fallot or pulmonary atresia, some patients continue to have increased pulmonary vascular resistance due to hypoplasia of the pulmonary vascular bed without major anatomical obstruction.

Pathobiology

Disturbances of the vascular endothelial function of pulmonary arteries and arterioles can be demonstrated in both iPAH and PAH secondary to CHD.[6] While the initiating stimulus of iPAH is unknown, the stimulus for the development of PAH in CHD is the pressure and volume load on the pulmonary vascular bed. Structural changes of pulmonary vascular disease are observed in both iPAH and PAH secondary to CHD. The histologic findings of pulmonary vascular disease in patients with fatal Eisenmenger syndrome were found to be associated with fibrinoid necrosis of the small pulmonary arteries and arterioles.[35]

Risk factors

In neonates with CHD, the severity and rate of progression of PAH can be determined by 3 risk factors: magnitude of pulmonary blood flow, elevation of pulmonary artery pressure, and arterial hypoxemia.[34,36] Neonates with lesions such as truncus arteriosus or transposition of the great arteries with ventricular septal defect, and lesions with 3 risk factors listed above, can therefore develop irreversible pulmonary vascular disease earlier in life.[7] In addition, children with Down syndrome and CHD seem to have an added risk factor for PAH due to pulmonary alveolar hypoplasia and chronic upper airway obstruction.[37] There are evidences showing that younger children with iPAH appear to have a more reactive pulmonary vascular bed relative to both active pulmonary vasodilatation and pulmonary vasoconstriction, with severe acute pulmonary hypertensive crises occurring in response to pulmonary vasoconstrictor "triggers" more often than in older children or adults.[4,5]

Evaluation

Clinical manifestations

The clinical manifestations of PAH in CHD are related to type and size of congenital heart defects, patients' age, severity of PAH, direction of the shunt, and state of repair. The presenting symptoms of PAH are nonspecific, including exertional dyspnea, fatigue, chest pain, palpitation, hemoptysis, and syncope. Exertional breathlessness is due to inability of the right ventricle to increase in cardiac output with metabolic demand.[1] In Eisenmenger syndrome, cyanosis and clubbing of fingers usually can be recognized from the right-to-left shunt. Chest pain can be caused by progressive right ventricular stress causing increased myocardial oxygen demand, critically elevated right ventricular systolic pressure reducing the pressure gradient from the epicardial right coronary artery to the subendocardium, thus reducing coronary flow, or extrinsic compression of the left main coronary artery from dilated pulmonary artery.[38-41] Orthopnea and paroxysmal nocturnal dyspnea due to elevated pulmonary venous pressure and pulmonary congestion in left heart diseases or left ventricular dysfunction may be presenting symptoms.

Physical examination

Physical findings include cyanosis at rest, right ventricular lift, palpable P2, loud P2 (frequently with a single loud second heart sound), a pulmonic ejection sound from the dilated pulmonary trunk, and a diastolic murmur of pulmonary insufficiency. Differential cyanosis may be presented if there is right-to-left shunt through patent ductus arteriosus and enter the aorta at or immediately beyond the left subclavian artery. The toes are cyanosed and clubbed. The right hand is acyanotic, and the fingers are not clubbed, whereas mild cyanosis and clubbing may be found in the left hand. In condition of transposition of the great arteries, patent ductus arteriosus, and suprasystemic pulmonary vascular resistance, reversed differential cyanosis may be presented. Pulmonary arterial blood with high oxygen content enter the aorta to the lower extremities resulting in less cyanotic feet compared to hands. In patients who had corrective surgery without residual lesion, physical findings are similar to those of patients with iPAH.

Transcutaneous oxygen saturation (SpO_2)

The systemic-to-pulmonary artery shunting lesions have normal arterial oxygen saturation until the reversal of the direction of the shunt develops. Differential cyanosis or reverse differential cyanosis can be detected by SpO_2 monitoring. All intraventricular mixing lesions such as single ventricle physiology have arterial oxygen desaturation whose degree of cyanosis depends on the degree of pulmonary stenosis and/or pulmonary vascular resistance which limits blood flow to the lungs.

The arterial oxygen saturation in most patients with iPAH physiology is normal. Some patients exhibit peripheral cyanosis related to the extraction of oxygen associated with low cardiac output and systemic vasoconstriction. Occasionally, there is a decrease in

arterial oxygen saturation because of a right-to-left shunt through patent foramen ovale or small atrial septal defect.

Electrocardiogram (ECG)

Except for abnormalities related to the underlying cardiac defect, ECG may also provide suggestive or supportive evidence of PAH. However, diagnostic yield for PAH is low.[2] The ECG findings include right axis deviation, right atrial enlargement, and right ventricular hypertrophy with secondary T-waves change.

Chest radiography

Radiographic manifestations in infants with left-to-right shunts include cardiomegaly, prominence of the pulmonary vasculature, and dilatation of the central pulmonary arteries.[42] With the severe and longstanding process, this shunt flow decreases and reverses, resulting in peripheral pruning of pulmonary vessels.[42] Signs of right atrial and right ventricular enlargement and calcification of the central pulmonary arteries may also present. In addition, as the pulmonary vascular resistance increases, if the congenital heart defect is not corrected, the heart size may decrease because of a smaller left-to-right shunt.

Transthoracic echocardiography

Echocardiography is useful for initial evaluation and follow-up of the treatment. Cardiac defects, level of shunting, degree and direction of shunts, severity of PAH, and ventricular function can be delineated systematically. Abnormal motion of the interventricular septum in parasternal short-axis views of the left ventricle has been described as an echocardiographic feature of right ventricular pressure overload if the interventricular septum is flattened and bulges toward the left ventricle (D-shape left ventricle in parasternal short-axis view) throughout the cardiac cycle.[43] The eccentricity index measures the degree of septal displacement and is defined as the ratio of the length of two-perpendicular minor-axis diameters, one of which is bisected and perpendicular to the interventricular septum. The eccentricity index greater than 1.0 at both end-systole and end-diastole suggests right ventricular pressure overload. Estimation of pulmonary artery pressure from Doppler pressure gradients across the tricuspid valve provides non-invasive hemodynamic data which are correlated well with invasive cardiac catheterization data.[2] The Tei index which is the sum of the isovolumetric contraction time and isovolumetric relaxation time, devided by the ejection time, assesses both systolic and diastolic right ventricular function.[41,44] The tricuspid annular plane systolic excursion (TAPSE) correlates with the right ventricular ejection fraction.[44]

Cardiac catheterization

Invasive assessment by cardiac catheterization shows disease severity by determining the pulmonary artery pressure, pulmonary vascular resistance, and the vasoreactivity of the pulmonary vasculature. However, major complications including acute pulmonary hypertensive crisis, and death may occur. Taylor et al[45] reported the incidence of resuscitation and death in 5.3% and 1.3% of children with both primary and secondary PAH during cardiac catheterization under general anesthesia. Carmosino et al[46] reported pulmonary hypertensive crisis in 4.3% of cardiac catheterization procedures. The risk of the procedure should be weighted against the benefit of the information.

Complete anatomic and physiologic data of various forms of CHD including acute pulmonary vasoreactivity testing are important to determine the appropriate therapy and prognosis. Oxygen, nitric oxide inhalation, and prostanoid (intravenous and inhalation) are the vasodilating agents used to test pulmonary vascular reactivity in these patients.[47] Nitric oxide inhalation lowers mean pulmonary artery pressure and pulmonary vascular resistance irrespective of etiology of PAH.[48] Nitric oxide in a dose range of 5 to 40 parts per million (ppm) has been used in addition to 100% oxygen in preoperative evaluation of pulmonary vascular resistance in children with CHD.[49,50] Oral sildenafil also can be used for assessment of feasibility of corrective cardiac surgery.

An acute response to the pulmonary vasoreactivity testing is generally defined as a decrease in mean pulmonary artery pressure of at least 10 mmHg with the mean pulmonary artery pressure decreasing to 40 mmHg or below, accompanied by a normal or high cardiac output.[2] In patients with left-to-right shunt and reactive pulmonary vascular bed, selective pulmonary vasodilator results in increased pulmonary blood flow and unchanged pulmonary artery pressure. Some investigators consider a simultaneous decrease in both pulmonary vascular resistance and pulmonary-to-systemic vascular resistance ratio of more than 10%, indicating selective reactivity of the pulmonary vascular bed.[51] The responsiveness of inhaled nitric oxide in adult patients with PAH and/or Eisenmenger syndrome was shown to be related to cardiopulmonary death and may be important risk stratification.[52]

Pulmonary wedge angiography is useful for evaluation of the pulmonary vascular bed in patients with CHD and PAH.[53] Typically, pulmonary angiography demonstrates large central pulmonary arteries with marked peripheral tapering. However, this procedure carries an increased risk in patients with PAH.

Cardiac magnetic resonance imaging or high-resolution computed tomography

Magnetic resonance imaging is superior to echocardio-

graphy in delineating cardiac anatomy both before and after cardiac surgery, particularly in patients with poor echocardiographic windows. Functional assessment is readily combined with the anatomical data. The advantages include noninvasiveness, good reproducibility, and no ionizing radiation. Various magnetic resonance techniques such as magnetic resonance angiography, perfusion imaging, and ventilation imaging have been used to evaluate the pulmonary vasculature and cardiac structure. In addition, magnetic resonance imaging provides information on right ventricular volume, mass, and function, valvular regurgitation, and extracardiac conduits.

Computed tomography provides excellent evaluation of the pulmonary vasculature, mediastinal structure, and lung parenchyma. High-resolution computed tomography is useful to assess pulmonary arterial thrombi, intrapulmonary hemorrhage or infarction in patients with PAH. Main pulmonary artery diameter has a good predictive value regarding the severity of PAH.[54] Pulmonary neovascularity finding (small, tortuous intrapulmonary vessels), lobular ground-glass opacification, and hilar and intercostal systemic collaterals were more prevalent in Eisenmenger syndrome, with greater severity in posttricuspid communication.[55] In contrast to magnetic resonance imaging, functional information such as ventricular function, flow, shunt, and regurgitant fraction are limited with computed tomography. In addition, radiation exposure and the use of iodinated contrast media are necessary with computed tomography.

Treatment

General management

Because physical activity is associated with increased pulmonary artery pressure, competitive sports are not recommended. Isometric activities such as lifting weights or stair climbing should be avoided. The balance of fluids should be preserved. Dehydration and excessive diuretics should be avoided. Decongestants with alpha-adrenergic properties are not suitable in this situation.[30] Long-term oxygen therapy is not routinely recommended although it is associated with improved subjective status in some patients.[29]

There is an association between an increased incidence of transient ischemic attacks and stroke and iron deficiency anemia. Iron deficiency anemia should be treated with oral iron supplementation. Some centers use transferrin saturation and serum ferritin instead of mean red cell volume in detection of iron depletion in this setting.[56]

Phlebotomy with replacement of fluid such as plasma or albumin is indicated in patients with severe hypoxemia with symptomatic erythrocytosis. However, routine phlebotomy should be discouraged because of depletion of iron stores and reduction of the circulating blood volume.[30]

Pregnancy carries significant risk for patients with Eisenmenger physiology with maternal death reported up to 50%.[19] Oral contraceptives should not be used and the most effective form of contraception for most patients is surgical sterilization.[30]

PAH has been associated with an increased risk of perioperative cardiovascular complication. The proposed mechanism is a rapid increase in pulmonary vascular resistance related to pulmonary vasoreactivity that can lead to a pulmonary hypertensive crisis and/or right heart failure. The hemodynamic and pulmonary vascular effects of anesthetic drugs are of particular concern. Baseline suprasystemic PAH is a significant predictor of major complications including cardiac arrest, pulmonary hypertensive crisis, and death.[46]

Medical treatment (Table 5)

There are 3 major pathways involved in abnormal proliferation and contraction of smooth muscle cells of the pulmonary artery in patients with PAH. These pathways correspond to important therapeutic drugs which are designed to augment prostacyclin and nitric oxide systems or block the endothelin effects (Fig. 2):[57] prostacyclin pathway (prostacyclin analogues), endothelin pathway (endothelin-receptor antagonists), and nitric oxide pathway (phosphodiesterase type 5 inhibitor and exogenous nitric oxide).

Prostacyclin analogues

Several compounds and administration methods of prostacyclin (prostaglandin I_2) analogues have been studied in the treatment of both iPAH and PAH secondary to CHD. Prostacyclin induces relaxation of vascular smooth muscle by stimulating the production of cyclic adenosine monophosphate (cAMP).[57] In addition, it is an inhibitor of platelet aggregation and smooth muscle cell proliferation.

1. Intravenous epoprostenol

Chronic intravenously infused epoprostenol lowers pulmonary vascular resistance and improves symptoms and survival in adults with iPAH.[58] Epoprostenol has been proven to improve survival, functional class, and exercise capacity in children with iPAH and secondary PAH.[59] Because of very short half-life, continuous intravenous infusion is required which increases complications from the complex delivery system. Therapy should never be abruptly withdrawn so as to avoid severe or fatal pulmonary hypertension.

The optimal dose of intravenous epoprostenol in children is unclear. The recommended starting dose is 1-2

ng/kg per minute, with dose increment of 1-2 ng/kg per minute every 15 minutes or longer until the appearance of dose-limiting side effects. Incremental increases occur more frequently during the first few months after administration of epoprostenol. The mean chronic dose at 1 year of therapy is 20-40 ng/kg per minute in adults, but it is 50-80 ng/kg per minute in children (particularly younger children). Significant patient variability in optimal dose occurs in pediatric patients.[5,60,61]

2. Treprostinil

Treprostinil is a stable prostacyclin analogue, with a half-life of 3 hours.[62] It is infused subcutaneously or intravenously. Continuous intravenous treprostinil in adult patients with PAH (idiopathic, or associated with connective tissue disease or CHD) could increase 6-minute-walk distance, treadmill time, Borg dyspnea score, and cardiopulmonary hemodynamics at week 12 compared with baseline.[63] The recommended dose for continuous subcutaneous treprostinil is 1.25 ng/kg per minute, with dose increment of 1.25 ng/kg per minute weekly to desired effect.[61] The usual maximum dose is 40 ng/kg per minute.[61] Short-term transition from intravenous epoprostenol to intravenous treprostinil has shown to be safe and effective in adult patients.[64]

3. Inhaled iloprost

Inhaled iloprost is a stable prostacyclin analogue, with a

Table 5. Treatment of pulmonary arterial hypertension

Name of drug	Drug class	Route of administration	Dosage/regimen	Maximum dose	Common side effects	Comments
Epoprostenol	Prostacyclin analogue	IV	IV continuous: start 1-2 ng/kg per min, increase 1-2 ng/kg per min q 15 min until dose-limiting side effects, then titrate to efficacy q 2 weeks (usually up to 20-40 ng/kg per min in adults, and 50-80 ng/kg per min in children)	80 ng/kg per min	Catheter infection and malfunction; side effects related to prostacyclin*	Tachyphylaxis: the need for increased doses with chronic use; stable long-term IV access needed; abrupt withdrawal can cause severe/fatal PAH; effective in patients with severe PAH and RHF
Treprostinil	Prostacyclin analogue	IV, SC	SC continuous: start 1.25 ng/kg per min, increase weekly by 1.25 ng/kg per min to desired effect	Limited experience with doses >40 ng/kg per min	Catheter infection and malfunction; infusion site pain and erythema; side effects related to prostacyclin*	-
Iloprost	Prostacyclin analogue	Inhaled	2.5-5 mcg/inhalation, 10-15 min, 6-9 times daily	7.5 mcg/ inhalation; maximum daily dose is 45 mcg	Cough; side effects related to prostacyclin*	Selective delivery of prostacyclin to lungs; need for frequent treatments
Beraprost sodium	Prostacyclin analogue	Oral	Start 1 mcg/kg per day, increase as tolerated	4 mcg/kg per day	Side effects related to prostacyclin*	-
Bosentan	Endothelin-receptor antagonist	Oral	<10 kg: 15.625 mg qd × 4 weeks, then increase to 15.625 mg bid; 10-20 kg: 31.25 mg qd × 4 weeks, then increase to 31.25 mg bid; 20-40 kg: 31.25 mg bid × 4 weeks, then increase to 62.5 mg bid; >40 kg: 62.5 mg bid × 4 weeks, then increase to 125 mg bid	125 mg bid	Hepatocellular injury, anemia, headache, flushing, edema, nasopharyngitis, teratogenic effects	Need LFTs checked monthly; primarily metabolized through cytochrome P450 isoenzyme systems; contraindicated in pregnancy
Sildenafil	Phosphodiesterase type 5 inhibitor	Oral	Start at a dose of 0.25-0.5 mg/kg q 4-8 hours, then titrate if needed and if tolerated to a dose of 1 mg/ kg q 4-8 hours	A dose of 2 mg/kg q 4 hours	Hypotension, epitaxis, headache, flushing, nausea, diarrhea, blurred vision; rare cases of sudden vision loss attributed to nonarteritic ischemic optic neuropathy (NAION) have been reported when used for treatment of male erectile dysfunction	Contraindicated with nitrates (additive hypotensive effects)
Nitric oxide	Potent selective pulmonary vasodilator	Inhaled	5-40 parts per million	80 parts per million	Methemoglobin production, impaired platelet aggregation	Monitor methemoglobin level; abrupt withdrawal may cause severe rebound PAH

bid: two times daily; IV: intravenous; kg: kilogram; LFTs: liver function tests; mcg: microgram; mg: milligram; min: minute; ng: nanogram; PAH: pulmonary arterial hypertension; q: every; qd: daily; qid: four times daily; RHF: right heart failure; SC: subcutaneous. *: side effects related to prostacyclin: jaw pain, headache, flushing, nausea, diarrhea.

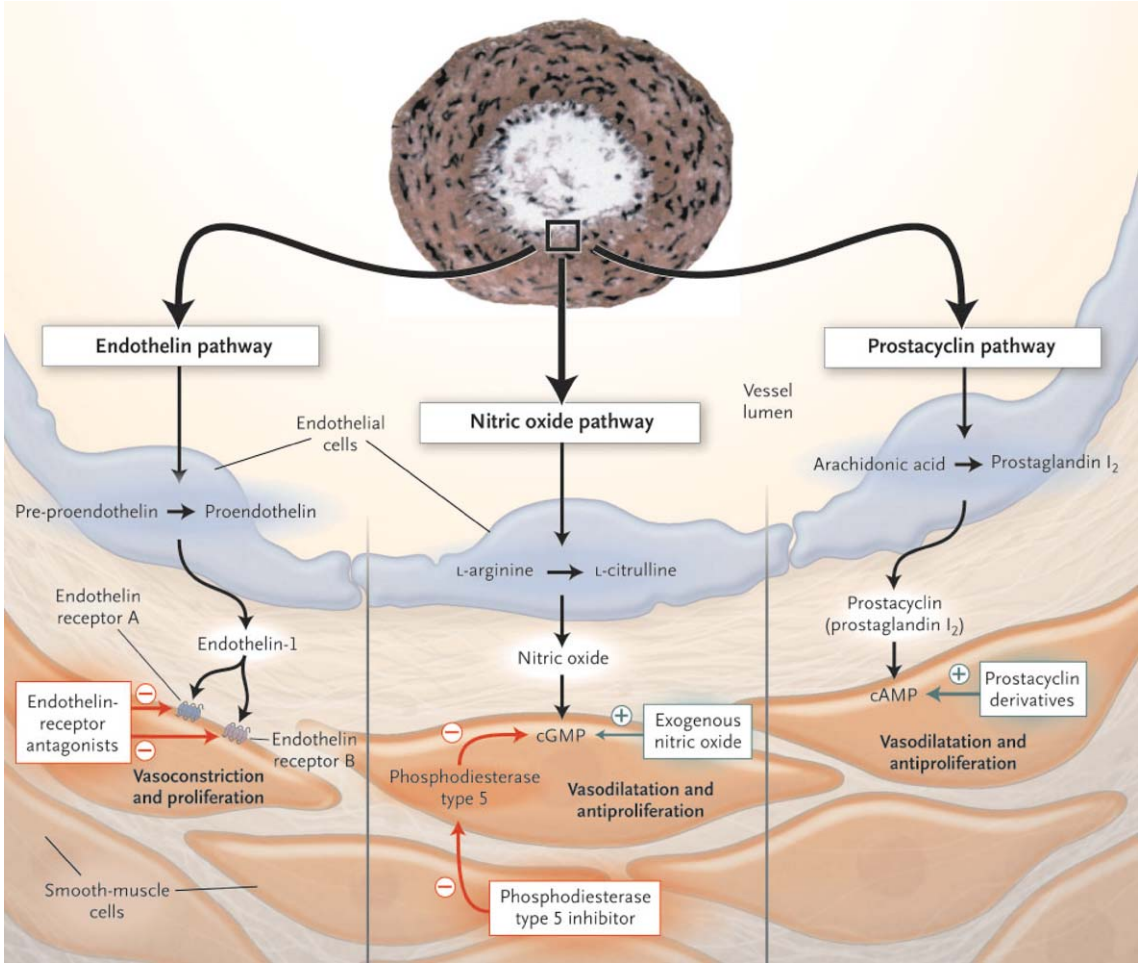

Fig. 2. Targets for current or emerging therapies in pulmonary arterial hypertension. (Adapted from Humbert et al[57] with permission)

half-life of 20 to 25 minutes.[62] It needs to be delivered in 6 to 9 inhalations per day. Each inhalation requires 10 to 15 minutes. The usual dose in adults is 2.5-5 mcg per inhalation.[65] The maximum daily dose is 45 mcg. Inhaled iloprost has been shown to be effective in increased 6-minute-walk distance, decreased pulmonary artery pressure and pulmonary vascular resistance, and improved cardiac output in adults with iPAH.[66] There is mild adverse effect including cough, headache, and jaw pain.

Ivy et al[67] reported the short- and long-term outcome of inhaled iloprost in 22 children with PAH (iPAH and secondary to CHD). They found that acute administration of inhaled iloprost lowered mean pulmonary artery pressure equivalent to the response to inhaled nitric oxide with oxygen although inhaled iloprost occasionally induced bronchoconstriction. The dose of inhaled iloprost was 2.5-7.5 mcg per inhalation, 5 to 9 inhalations daily. At 6 months, World Health Organization (WHO) functional class improved in 35%, decreased in 15%, and remained unchanged in 50% of children. The transition from intravenous to inhaled prostacyclin therapy was tolerated in most patients.

4. Beraprost sodium

Beraprost sodium is an orally active prostacyclin analogue. Beraprost sodium in children with CHD has been found to be associated with reduction of the pulmonary-to-systemic vascular resistance ratio and insignificant change in pulmonary artery pressure, which lead to an increase in intracardiac shunt.[68] Beraprost sodium has been demonstrated to improve exercise capacity and Borg dyspnea score in New York Heart Association (NYHA) functional class II and III in adolescent and adult patients with PAH, in particular, in those with iPAH in a prospective, double-blind, randomized, placebo-controlled, 12-week trial.[69] However, these beneficial effects may occur during early phases of treatment and attenuates with time.[70] The recommended initial dose is 1 mcg/kg per day up to a maximum dose of 4 mcg/kg per day.[68,71]

The combination of oral beraprost sodium

and inhaled iloprost was shown to have beneficial hemodynamic effects on the lung vasculature and reducing systemic side effects while improving the 6-minute-walk distance and reducing right ventricular systolic pressure in pediatric and adult patients with PAH secondary to CHD.[71]

Endothelin-receptor antagonists

Endothelin (ET)-1 is a highly potent *in vitro* and *in vivo* vasoconstrictor and a smooth muscle mitogen. There are 2 endothelin receptor subtypes identified, receptors A and B.[72] The ET_A receptors are expressed on pulmonary vascular smooth muscle cells and mediate vasoconstriction and proliferation. The ET_B receptors mediate endothelium-dependent vasodilatation through the release of nitric oxide, prostacyclin, and adrenomodullin. The ET_B receptors can also cause vasoconstriction.[73] iPAH and secondary PAH are associated with increased ET-1 level in plasma and lung tissue.[3,74,75]

1. Bosentan

Bosentan is an orally active, competitive antagonist of both ET_A and ET_B receptors, with a slightly higher affinity for the ET_A receptor. Bosentan diminishes endothelin-induced smooth muscle cell contraction, hypertrophy and hyperplasia, and fibrosis and reduces both the hemodynamic and structural response to experimentally induced pulmonary hypertension. In 2002, bosentan was shown to be safe and efficacious in the treatment of adults with PAH.[76]

Experience of bosentan use in children showed that bosentan helped stabilize in iPAH but intravenous epoprostenol was needed for combined treatment. Children with secondary PAH improved WHO functional class and 6-minute-walk test significantly.[77] In addition, bosentan associated with decreased right ventricular systolic pressure was demonstrated in infants and young children with PAH secondary to CHD.[78] Bosentan use in small infants without significant adverse effects was also reported.[79]

Votava-Smith et al[80] reported the successful use of bosentan for increased pulmonary vascular resistance in a 10-year-old boy who underwent late bidirectional Glenn shunt for double-inlet left ventricle, with unobstructed pulmonary blood flow. After 16 weeks of bosentan therapy, the decrease in mean pulmonary artery pressure and transpulmonary gradient allowed for improvements in cardiopulmonary exercise test and symptoms.

In adult patients with severe PAH related to CHD, there were significant improvement in clinical status, exercise tolerance, and pulmonary hemodynamics after short- and mid-term bosentan therapy.[81-87] Bosentan therapy for adults with Eisenmenger syndrome also resulted in improvement of oxygenation and subjective functional status.[88,89] However, objective exercise parameters appeared to slowly return to baseline value at 2 years of follow-up.[90,91]

The Bosentan Randomized Trial of Endothelin Antagonist Therapy-5 (BREATH-5) was a 16-week, multicenter, randomized, double-blind, placebo-controlled study in adolescent and adult patients with WHO functional class III Eisenmenger syndrome.[92] Bosentan was well tolerated and improved exercise capacity and hemodynamics without compromising transcutaneous oxygen saturation.

The endothelin antagonist trial in mildly symptomatic pulmonary arterial hypertension patients (EARLY) study was a prospective, randomized, double-blind, controlled trial in patients with WHO functional class II PAH (idiopathic, and secondary).[93] At 6 months, the decrease in mean pulmonary vascular resistance and increase in the 6-minute-walk distance were demonstrated in the bosentan group.

The dosage of bosentan in children is based on pediatric studies: <10 kg: 15.625 mg daily for 4 weeks, which is then increased to a maintenance dose of 15.625 mg twice daily; 10-20 kg: 31.25 mg daily for 4 weeks, then increased to a maintenance dose of 31.25 mg twice daily; 20-40 kg: 31.25 mg twice daily for 4 weeks, then increased to a maintenance dose of 62.5 mg twice daily; >40 kg: 62.5 mg twice daily for 4 weeks, then increased to a maintenance dose of 125 mg twice daily.[60,61,94]

Elevation in liver aminotransferases, i.e., aspartate and/or alanine aminotransferases (AST and/or ALT), associated with bosentan use is documented in a minor percentage of patients. Aminotransferase levels must be measured before and during the treatment with bosentan.

2. Sitaxsentan

Sitaxsentan is an oral ET_A selective endothelin-receptor antagonist. The STRIDE-1 and STRIDE-2 study (Sitaxsentan To Relieve Impaired Exercise), double-blind, placebo-controlled, sitaxsentan has been shown significant benefit in 6-minute-walk distance, WHO functional class, and hemodynamics in adult patients with PAH (idiopathic, or associated with connective tissue disease or CHD).[95,96] Long-term follow-up to 1 year also showed improvement in these parameters without serious adverse events.[97] Sitaxsentan was shown to be safe and efficacious for whom they discontinued bosentan because of inadequate efficacy or hepatotoxicity.[98] There is no reported use of sitaxsentan in children with PAH.

3. Ambrisentan

Ambrisentan, an oral ET_A selective endothelin-receptor antagonist, improved exercise capacity, symptoms, and hemodynamics in adult patients with iPAH and PAH

associated with collagen vascular disease, anorexigen use, and human immunodeficiency virus infection while the incidence of elevated liver aminotransferases appeared to be low.[99] Data of ambrisentan use in children are still lacking.

Phosphodiesterase type 5 inhibitors and exogenous nitric oxide

1. Sildenafil

Sildenafil is a selective inhibitor of phosphodiesterase type 5 (PDE5) which is found in high concentrations in the lungs. PDE5 inhibitors act as a "nitric oxide donor". Inhibition of PDE5 enhances the vasodilatory effects of nitric oxide in PAH by preventing the degradation of cyclic guanosine monophosphate (cGMP) while promoting relaxation of vascular smooth muscle.[57] Sildenafil has recently been used as an alternative to traditional therapies in many forms of PAH in adults and children.

The randomized, double-blind, placebo-controlled study (SUPER Study; Sildenafil Use in Pulmonary Arterial Hypertension)[100] included 278 adult patients with PAH (either idiopathic or associated with connective tissue disease or with repaired congenital systemic-to-pulmonary shunts) in WHO functional class II to IV. They were assigned to receive placebo or sildenafil (20, 40, or 80 mg) orally 3 times daily for 12 weeks. At week 12, the sildenafil group showed improved exercise capacity, WHO functional class, and pulmonary hemodynamics. Most adverse effects, such as headache, flushing, myalgia, dyspepsia, and diarrhea, were mild to moderate and well tolerated.

Sildenafil has been shown to improve exercise capacity and functional class in pediatric and adult patients with iPAH and Eisenmenger physiology.[101,102] In Fontan patients, oral administration of a single dose of sildenafil improves exercise capacity and hemodynamic response to exercise.[103] Sildenafil decreases pulmonary artery pressure without significant effect on systemic arterial pressure during postoperative period in children.[104,105] Sildenafil response during postoperative pulmonary hypertension in some patients who had severe PAH, non-responsive to nitric oxide which suggests overactivity of cGMP-degrading PDE5 may be a more important risk factor than a decrease endogenous nitric oxide production.[106] In addition, sildenafil has been reported to prevent rebound PAH after withdrawal of inhaled nitric oxide in children.[106,107] Intravenous sildenafil potentiated in increased cGMP in response to inhaled nitric oxide by PDE5 inhibition was demonstrated during cardiac catheterization and postoperative period in infants and children with CHD and high pulmonary vascular resistance.[108,109] Medium-term treatment with oral sildenafil in children was found promising.[110]

The use of sildenafil in infants and children with PAH is indicated in iPAH, persistent pulmonary hypertension of the newborn refractory to treatment with inhaled nitric oxide, to attenuate rebound effects after discontinuing inhaled nitric oxide, and secondary PAH following cardiac surgery.[60,105-107,111] Based on the case reports and small studies in pediatric population, an initial dose of 0.25-0.5 mg/kg every 4-8 hours is recommended for infants and children. Dose titration if needed and if tolerated to a dose of 1 mg/kg every 4-8 hours has been reported.[60,61] Doses up to 2 mg/kg every 4 hours have been used in severe cases.[110]

2. Nitric oxide

Nitric oxide as a potent selective pulmonary vasodilator exerts antiproliferative effects on pulmonary vascular smooth muscle cells. Nitric oxide is mediated by the guanylyl cyclase/cGMP pathway.[112]

Immediate postoperative or "reactive" PAH is associated with high morbidity and mortality for severe PAH patients who have undergone corrective cardiac surgery. Hypoxia-induced pulmonary vasoconstriction should be avoided.[113] Data in children with CHD with increased pulmonary blood flow have shown that nitric oxide-related compound affects the hemodynamic status and degree of pulmonary vascular disease.[114,115] Inhaled nitric oxide has been demonstrated to reduce the pulmonary artery pressure and frequency of pulmonary hypertensive crisis, improve oxygenation, and shorten time to extubation.[116-122] However, some studies have shown that inhaled nitric oxide does not improve pulmonary hemodynamics or survival after operation for CHD with severe PAH.[123,124] The recommended dose is 5-40 ppm, up to a maximum dose of 80 ppm.[61] Abrupt withdrawal of therapy may cause severe rebound PAH. In addition, the potential toxicity of methemoglobin should be monitored.

The clinical experience with long-term inhaled nitric oxide therapy is limited. There is evidence showing a progressive rebound of symptoms during long-term treatment.[125]

3. Nitroglycerin

Nitroglycerin inhalation as a nitric oxide donor decreases systolic, diastolic, and mean pulmonary artery pressure and pulmonary vascular resistance index without affecting systemic hemodynamics during cardiac catheterization and may be an alternative treatment for acute reduction of PAH in children with CHD.[126,127]

Combination therapy

Because of various mechanisms involving in pathogenesis and pathophysiology of PAH, combination

of drugs with different mechanisms of action was found effective (Fig. 2).[3,57] The combination of these medications should be reserved for selected patients who do not respond to monotherapy or for those who are initially benefited but then deteriorated on a single agent.[128]

Long-term bosentan therapy, with or without concomitant intravenous epoprostenol or subcutaneous treprostinil therapy, has shown to be safe and effective in children with PAH (idiopathic, associated with CHD, or connective tissue disease).[129]

Oral sildenafil as adjunctive therapy to inhaled iloprost in adult patients with severe PAH, iPAH and PAH associated with collagen vascular disease improves exercise capacity and pulmonary hemodynamics.[130] Bosentan and sildenafil combination has also shown improved NYHA functional class, exercise capacity, and pulmonary hemodynamics in various forms of PAH in children and adults.[131]

Anticoagulation

Anticoagulation with warfarin has been proved useful in adult iPAH patients.[65,132] However, no data are available from children with Eisenmenger syndrome. Some cases of Eisenmenger syndrome have *in situ* thrombosis. The risk and benefit of anticoagulation should be weighted with the likelihood of hemoptysis in these specific group of patients.

Aspirin and clopidogrel inhibit platelet aggregation in patients with iPAH. Aspirin reduces thromboxane metabolite production without affecting prostaglandin I_2 metabolite synthesis. The clinical benefit and safety of long-term aspirin therapy in PAH are unknown.[133]

Other potential therapy

There is an evidence showing that cardiopulmonary bypass significantly decreases availability of nitric oxide precursors, arginine and citrulline, in the postoperative period and may contribute to the increased risk of postoperative pulmonary hypertension.[134] Some early clinical studies suggest that oral and intravenous citrulline may be effective in reducing postoperative PAH in infants and children.[135,136] Intravenous citrulline as a potential therapy for postoperative PAH is now under phase III clinical trials.

Interventional treatment

Atrial septostomy

Atrial septostomy, blade balloon atrial septostomy, and graded balloon-dilation atrial septostomy were indicated in refractory PAH associated with right ventricular failure, as a bridge to transplantation, or the absence of other therapeutic options.[137] The procedure should be performed only in institutions with experience in performing atrial septostomy with a low rate of morbidity. Creation of right-to-left shunt increases cardiac output and, despite the fall in systemic arterial oxygen saturation, augments systemic oxygen transport at rest and/or with exercise. The shunt decompresses the right heart, reduces right ventricular end diastolic pressure or wall stress, and ameliorates right ventricular failure in selected patients. It remains unclear whether use of atrial septostomy is better tolerated or effective in patients previously exposed to intravascular shunting.[138]

Surgical treatment

Surgical closure of intracardiac defects with leaving an atrial level communication

Surgical closure in patients with severe PAH and high pulmonary vascular resistance associated CHD is known to carry significant mortality and morbidity. Recently, attempts have been made to close intracardiac defects with left patent foramen ovale or create atrial communication in many cardiac centers. In 2006, Khan et al[139] reported ventricular septal defect closure leaving patent foramen ovale or artificial atrial septal defect (5 mm) in 16 infants and children with large ventricular septal defect of elevated pulmonary vascular resistance. The overall mortality was 6.25%.

Surgical closure of intracardiac defects with "flap-valve" closure

In 1959, Bailey et al[140] applied "flap-valve" closure in patients with atrial and ventricular septal defects with severe PAH. The device allows decompression of the right heart whenever the right ventricular pressure exceeds systemic levels, thus preventing acute right heart failure.

In 1998, Novick et al[141] designed a fenestrated flap valve double ventricular septal defect patch (Fig. 3). The routine ventricular septal defect patch was fenestrated (4

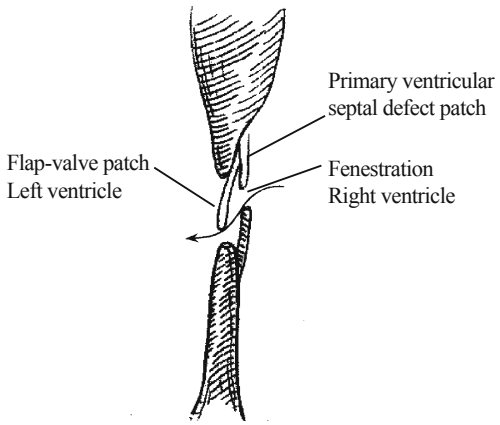

Fig. 3. Illustration of the double flap valve patch in profile with open valve. Lateral view of flap valve and ventricular septal defect patch. (Adapted from Zhang et al[144] with permission)

Table 6. Recipient survival after lung and heart lung transplantation (1990-2001)

Time	Survival by diagnosis and type of transplant					
	PPH		ES		Other CHD	
	LT (691, %)	HLT (302, %)	LT (196, %)	HLT (376, %)	LT (22, %)	HLT (155, %)
3 months	72	72	69	76	79	59
1 year	64	66	58	71	68	45
3 years	54	50	45	57	36	32
5 years	44	41	39	50	36	28
10 years	21	22	29	39	36	7

CHD: congenital heart disease; ES: Eisenmenger syndrome; HLT: heart and lung transplantation; LT: lung transplantation; PPH: primary (idiopathic) pulmonary arterial hypertension. (From Klepetko et al[137] with permission)

to 8 mm), and on the left ventricular side of the patch, a second smaller patch was attached to the upper third of the fenestration before ventricular septal defect patch placement. Ninety-one children with a large ventricular septal defect, as the primary or complex defects, and elevated pulmonary vascular resistance underwent operation; the overall early mortality rate was 7.7% (7 of 91) with 7 late deaths.[142] In the absence of sophisticated pharmacologic or mechanical intervention, these morbidity and mortality were considered reasonable.

Afrasiabi et al[143] and Zhang et al[144] reported the use of valve patch for repair of ventricular septal defect with high pulmonary vascular resistance in children. Early postoperative mortality was 7%-12.5% because of pulmonary hypertensive crisis with no late death. The survival patients had improved cardiopulmonary function and decreased pulmonary vascular resistance. A small amount of right-to-left shunt through the valve patch demonstrated by an echocardiography existed in some patients.

Transplantation

Heart and lung transplantation or lung transplantation in combination with repair of the underlying cardiac defect is a therapeutic option in selected patients. Survival rates from the International Society for Heart and Lung Transplantation registry are presented (Table 6).[137] In Eisenmenger syndrome secondary to ventricular septal defect, there was a highly significant survival benefit of heart and lung transplantation over lung transplantation.[145] However, some cardiac centers prefer to perform repair of CHD and lung transplantation to augment the donor pool and avoid the cardiac complications associated with heart transplantation. Freedoms from bronchiolitis obliterans and survivals were similar in both groups.[146] In Eisenmenger patients, the survival rate at 40, 50 and 60 years of age is 94%, 74% and 52%, respectively.[147] Transplantation may not give a better survival, though the quality of life may improve. The optimal timing for transplantation remains very difficult and there is no specific guideline. The high incidence of post-transplant bronchiolitis obliterans syndrome remains problematic.[148]

Conclusions

Among the different forms of congenital heart diseases, an early correction generally prevents subsequent development of pulmonary arterial hypertension. Emerging therapies for treatment of patients with idiopathic PAH also improve quality of life and survival in neonates and children with congenital heart disease associated with PAH. Heart and lung transplantation or lung transplantation in combination with repair of the underlying cardiac defect is a therapeutic option in a minority of patients. Partial repair options are also beneficial in some selected cases. Randomized controlled trials are needed to evaluate the safety and efficacy of these therapies including survival and long-term outcome.

Acknowledgement

We thank Grace Lee, pharmacist and clinical specialist, for expert assistance.

Funding: None.
Ethical approval: Not needed.
Competing interest: None declared.
Contributors: Suesaowalak M wrote the first draft of this paper. Cleary JP and Chang AC contributed to the intellectual content and approved the final version. Chang AC is the guarantor.

References

1 Barst RJ. Recent advances in the treatment of pediatric pulmonary artery hypertension. Pediatr Clin North Am 1999;46:331-345.
2 Barst RJ, McGoon M, Torbicki A, Sitbon O, Krowka MJ, Olschewski H, et al. Diagnosis and differential assessment of pulmonary arterial hypertension. J Am Coll Cardiol 2004;43:40S-47S.
3 Farber HW, Loscalzo J. Mechanisms of disease: pulmonary arterial hypertension. N Engl J Med 2004;351:1655-1665.

4 Ford K. Pulmonary artery hypertension: new drug treatment in children. Arch Dis Child Ed Pract 2005;90:ep15-ep20.
5 Widlitz A, Barst RJ. Pulmonary arterial hypertension in children. Eur Respir J 2003;21:155-176.
6 Schulze-Neick I, Deanfield JE. Pulmonary arterial hypertension in adults with congenital heart disease: general overview of disease mechanisms. Adv Pulmonary Hypertens 2007;6: 121-125.
7 Tulloh RM. Congenital heart disease in relation to pulmonary hypertension in paediatric practice. Paediatr Respir Rev 2005;6: 174-180.
8 Simonneau G, Galiè N, Rubin LJ, Langleben D, Seeger W, Domenighetti G, et al. Clinical classification of pulmonary hypertension. J Am Coll Cardiol 2004;43:5S-12S.
9 Galiè N. Classification of patients with congenital systemic-to-pulmonary shunts associated with pulmonary arterial hypertension: current status and future directions. In: Beghetti M, Barst RJ, Naeije R, Rubin LJ, eds. Pulmonary arterial hypertension related to congenital heart disease. Munich (Germany): Elsevier GmbH Deutschland, 2006: 11-17.
10 van Albada ME, Berger RM. Pulmonary arterial hypertension in congenital cardiac disease—the need for refinement of the Evian-Vanice classification. Cardiol Young 2008;18:10-17.
11 Schulze-Neick I, Beghetti M. Classifying pulmonary hypertension in the setting of the congenitally malformed heart—cleaning up a dog's dinner. Cardiol Young 2008;18: 22-25.
12 Heath D, Edwards JE. The pathology of hypertensive pulmonary vascular disease: a description of six grades of structural changes in the pulmonary arteries with special reference to congenital cardiac septal defects. Circulation 1958; 18:533-547.
13 Nagumo K, Yamaki S, Takahashi T. Extremely thickened media of small pulmonary arteries in fatal pulmonary hypertension with congenital heart disease—a morphometric and clinicopathological study. Jpn Circ J 2000;64:909-914.
14 Rabinovitch M, Haworth SG, Castaneda AR, Nadas AS, Reid LM. Lung biopsy in congenital heart disease: a morphometric approach to pulmonary vascular disease. Circulation 1978;58:1107-1122.
15 Rabinovitch M, Keane JF, Norwood WI, Castaneda AR, Reid L. Vascular structure in lung tissue obtained at biopsy correlated with pulmonary hemodynamic findings after repair of congenital heart defects. Circulation 1984;69:655-667.
16 Friedman WF, Heiferman MF. Clinical problems of postoperative pulmonary vascular disease. Am J Cardiol 1982; 50:631-636.
17 Haworth SG. Pulmonary vascular disease in different types of congenital heart disease: implications for interpretation of lung biopsy findings in early childhood. Br Heart J 1984;52:557-571.
18 Yamaki S, Endo M, Takahashi T. Different grades of medial hypertrophy and intimal changes in small pulmonary arteries among various types of congenital heart disease with pulmonary hypertension. Tohoku J Exp Med 1997;182:83-91.
19 Landzberg MJ. Congenital heart disease associated pulmonary arterial hypertension. Clin Chest Med 2007;28:243-253.
20 Wagenvoort CA. Lung biopsy specimens in the evaluation of pulmonary vascular disease. Chest 1980;77:614-625.
21 Yamaki S, Abe A, Endo M, Tanaka T, Tabayashi K, Takahashi T. Surgical indication for congenital heart disease with extremely thickened media of small pulmonary arteries. Ann Thorac Surg 1998;66:1560-1564.
22 Yamaki S, Abe A, Tabayashi K, Endo M, Mohri H, Takahashi T. Inoperable pulmonary vascular disease in infants with congenital heart disease. Ann Thorac Surg 1998;66:1565-1570.
23 Egito ES, Aiello VD, Bosisio IB, Lichtenfels AJ, Horta AL, Saldiva PH, et al. Vascular remodeling process in reversibility of pulmonary arterial hypertension secondary to congenital heart disease. Pathol Res Pract 2003;199:521-532.
24 Alt B, Shikes RH. Pulmonary hypertension in congenital heart disease: irreversible vascular changes in young infants. Pediatr Pathol 1983;1:423-434.
25 Newman JH, Phillips JA 3rd, Loyd JE. Narrative review: the enigma of pulmonary arterial hypertension: new insights from genetic studies. Ann Intern Med 2008;148:278-283.
26 Roberts KE, McElroy JJ, Wong WP, Yen E, Widlitz A, Barst RJ, et al. BMPR2 mutations in pulmonary arterial hypertension with congenital heart disease. Eur Respir J 2004;24:371-374.
27 Limsuwan A, Platoshyn O, Yu Y, Rubin LJ, Rothman A, Yuan JX. Inhibition of K(+) channel activity in human pulmonary artery smooth muscle cells by serum from patients with pulmonary hypertension secondary to congenital heart disease. Pediatr Res 2001;50:23-28.
28 Humbert M, Morrell NW, Archer SL, Stenmark KR, MacLean MR, Lang IM, et al. Cellular and molecular pathobiology of pulmonary arterial hypertension. J Am Coll Cardiol 2004;43: 13S-24S.
29 Diller GP, Gatzoulis MA. Pulmonary vascular disease in adults with congenital heart disease. Circulation 2007;115:1039-1050.
30 Rosenzweig EB, Barst RJ. Clinical management of patients with pulmonary hypertension. In: Allen HD, Driscoll DJ, Shaddy RE, Feltes TF, eds. Moss and Adams' heart disease in infants, children, and adolescents including the fetus and young adult, 7th ed. Philadelphia: Lippincott Williams & Wilkins, 2008: 1355-1368.
31 Daliento L, Somerville J, Presbitero P, Menti L, Brach-Prever S, Rizzoli G, et al. Eisenmenger syndrome: factors relating to deterioration and death. Eur Heart J 1998;19:1845-1855.
32 Gewillig M. The Fontan circulation. Heart 2005;91:839-846.
33 Santos MA, Azevedo VM. Anomalous origin of one pulmonary artery from the ascending aorta. Surgical repair resolving pulmonary arterial hypertension. Arq Bras Cardiol 2004; 83:503-507.
34 Robinovitch M. Pathophysiology of pulmonary hypertension. In: Allen HD, Driscoll DJ, Shaddy RE, Feltes TF, eds. Moss and Adams' heart disease in infants, children, and adolescents including the fetus and young adult, 7th ed. Philadelphia: Lippincott Williams & Wilkins, 2008: 1322-1354.
35 Daliento L, Rebellato L, Angelini A, Frescura C, Mazzotti E, Rotundo M, et al. Fatal outcome in Eisenmenger syndrome. Cardiovasc Pathol 2002;11:221-228.
36 Chang AC, Macrae D. Neonates with congenital cardiac defects and pulmonary hypertension. Cardiol Young 2009;19(Suppl 1):4-7.
37 Murphy AM, Neill CA, Zuckerberg AL. Syndromes and congenital heart defects. In: Nichols DG, Ungerleider RM, Spevak PJ, Greeley WJ, Cameron DE, Lappe DG, et al (eds). Critical heart disease in infants and children, 2nd ed. Philadelphia: Elsevier, 2006: 951-971.
38 Kajita LJ, Martinez EE, Ambrose JA, Lemos PA, Esteves A, Nogueira da Gama M, et al. Extrinsic compression of the left main coronary artery by a dilated pulmonary artery: clinical, angiographic, and hemodynamic determinants. Catheter Cardiovasc Interv 2001;52:49-54.

39 Piña Y, Exaire JE, Sandoval J. Left main coronary artery extrinsic compression syndrome: a combined intravascular ultrasound and pressure wire. J Invasive Cardiol 2006;18: E102-104.
40 Paç FA, Cağdas DN, Ulaş M, Ozatik MA, Paç M. Left main coronary artery and aortic root compression associated with atrial septal defect and pulmonary hypertension. Int J Cardiol 2007;118:e41-43.
41 McGoon MD, Kane GC. Pulmonary hypertension: diagnosis and management. Mayo Clin Proc 2009;84:191-207.
42 Randall PA, Heitzman ER, Bull MJ, Scalzetti EM, Williams SK, Gordon LP, et al. Pulmonary arterial hypertension: a contemporary review. Radiographics 1989;9:905-927.
43 Ryan T, Petrovic O, Dillon JC, Feigenbaum H, Conley MJ, Armstrong WF. An echocardiographic index for separation of right ventricular volume and pressure overload. J Am Coll Cardiol 1985;5:918-927.
44 Haworth SG. The management of pulmonary hypertension in children. Arch Dis Child 2008;93:620-625.
45 Taylor CJ, Derrick G, McEwan A, Haworth SG, Sury MR. Risk of cardiac catheterization under anaesthesia in children with pulmonary hypertension. Br J Anaesth 2007;98:657-661.
46 Carmosino MJ, Friesen RH, Doran A, Ivy DD. Perioperative complications in children with pulmonary hypertension undergoing noncardiac surgery or cardiac catheterization. Anesth Analg 2007;104:521-527.
47 Turanlahti MI, Laitinen PO, Sarna SJ, Pesonen E. Nitric oxide, oxygen, and prostacyclin in children with pulmonary hypertension. Heart 1998;79:169-174.
48 Krasuski RA, Warner JJ, Wang A, Harrison JK, Tapson VF, Bashore TM. Inhaled nitric oxide selectively dilates pulmonary vasculature in adult patients with pulmonary hypertension, irrespective of etiology. J Am Coll Cardiol 2000;36:2204-2211.
49 Yasuda T, Tauchi N, Baba R, Nishibata K, Hatano T, Nakamura S, et al. Inhalation of low-dose nitric oxide to evaluate pulmonary vascular reactivity in children with congenital heart disease. Pediatr Cardiol 1999;20:278-282.
50 Cannon BC, Feltes TF, Fraley JK, Grifka RG, Riddle EM, Kovalchin JP. Nitric oxide in the evaluation of congenital heart disease with pulmonary hypertension: factors related to nitric oxide response. Pediatr Cardiol 2005;26:565-569.
51 Berner M, Beghetti M, Spahr-Schopfer I, Oberhansli I, Friedli B. Inhaled nitric oxide to test the vasodilator capacity of the pulmonary vascular bed in children with long-standing pulmonary hypertension and congenital heart disease. Am J Cardiol 1996;77:532-535.
52 Post MC, Janssens S, Van de Werf F, Budts W. Responsiveness to inhaled nitric oxide is a predictor for mid-term survival in adult patients with congenital heart defects and pulmonary arterial hypertension. Eur Heart J 2004;25:1651-1656.
53 Fujiyama J, Yoshida Y, Ogata H, Kato T, Kuteken O, Oyama K. Pulmonary wedge angiography for the evaluation of the pulmonary vascular bed in congenital heart disease. Cathet Cardiovasc Diagn 1984;10:237-246.
54 Grubstein A, Benjaminov O, Dayan DB, Shitrit D, Cohen M, Kramer MR. Computed tomography angiography in pulmonary hypertension. Isr Med Assoc J 2008;10:117-120.
55 Sheehan R, Perloff JK, Fishbein MC, Gjertson D, Aberle DR. Pulmonary neovascularity: a distinctive radiographic finding in Eisenmenger syndrome. Circulation 2005;112:2778-2785.
56 Barst RJ, Fineman JR, Gatzoulis MA, Krasuski RA. Pulmonary hypertension roundtable: pulmonary arterial hypertension in adults with congenital heart disease. Adv Pulmonary Hypertens 2007;6:142-148.
57 Humbert M, Sitbon O, Simonneau G. Treatment of pulmonary arterial hypertension. N Engl J Med 2004;351:1425-1436.
58 McLaughlin VV, Genthner DE, Panella MM, Rich S. Reduction in pulmonary vascular resistance with long-term epoprostenol (prostacyclin) therapy in primary pulmonary hypertension. N Engl J Med 1998;338:273-277.
59 Lammers AE, Hislop AA, Flynn Y, Haworth SG. Epoprostenol treatment in children with severe pulmonary hypertension. Heart 2007;93:739-743.
60 Taketomo CK, Hodding JH, Kraus DM. Pediatric dosage handbook: including neonatal dosing, drug administration, & extemporaneous preparations, 13th ed. Ohio: Lexi-Comp Inc., 2006.
61 Dent CL. Pulmonary hypertension in children. In: Burg FD, Ingelfinger JR, Polin RA, Gershon AA, eds. Current pediatric therapy, 18th ed. Philadelphia: Elsevier Inc., 2006: 503-510.
62 Badesch DB, McLaughlin VV, Delcroix M, Vizza CD, Olschewski H, Sitbon O, et al. Prostanoid therapy for pulmonary arterial hypertension. J Am Coll Cardiol 2004;43: 56S-61S.
63 Tapson VF, Gomberg-Maitland M, McLaughlin VV, Benza RL, Widlitz AC, Krichman A, et al. Safety and efficacy of IV treprostinil for pulmonary arterial hypertension: a prospective, multicenter, open-label, 12-week trial. Chest 2006;129:683-688.
64 Gomberg-Maitland M, Tapson VF, Benza RL, McLaughlin VV, Krichman A, Widlitz AC, et al. Transition from intravenous epoprostenol to intravenous treprostinil in pulmonary hypertension. Am J Respir Crit Care Med 2005;172:1586-1589.
65 Park MH. Advances in diagnosis and treatment in patients with pulmonary arterial hypertension. Catheter Cardiovasc Interv 2008;71:205-213.
66 Hoeper MM, Schwarze M, Ehlerding S, Adler-Schuermeyer A, Spiekerkoetter E, Niedermeyer J, et al. Long-term treatment of primary pulmonary hypertension with aerosolized iloprost, a prostacyclin analogue. N Engl J Med 2000;342:1866-1870.
67 Ivy DD, Doran AK, Smith KJ, Mallory GB Jr, Beghetti M, Barst RJ, et al. Short- and long-term effects of inhaled iloprost therapy in children with pulmonary arterial hypertension. J Am Coll Cardiol 2008;51:161-169.
68 Limsuwan A, Pienvichit P, Khowsathit P. Beraprost therapy in children with pulmonary hypertension secondary to congenital heart disease. Pediatr Cardiol 2005;26:787-791.
69 Galiè N, Humbert M, Vachiéry JL, Vizza CD, Kneussl M, Manes A, et al. Effects of beraprost sodium, an oral prostacyclin analogue, in patients with pulmonary arterial hypertension: a randomized, double-blind, placebo-controlled trial. J Am Coll Cardiol 2002;39:1496-1502.
70 Barst RJ, McGoon M, McLaughlin V, Tapson V, Oudiz R, Shapiro S, et al. Beraprost therapy for pulmonary arterial hypertension. J Am Coll Cardiol 2003;41:2119-2125.
71 Durongpisitkul K, Jakrapanichakul D, Laohaprasitiporn D, Soongswang J, Chanthong P, Nana A. Combination therapy of prostacyclin for pulmonary hypertension in congenital heart disease. J Med Assoc Thai 2005;88(Suppl 8):S60-65.
72 Roux S, Breu V, Ertel SI, Clozel M. Endothelin antagonism with bosentan: a review of potential applications. J Mol Med 1999;77:364-376.
73 Channick RN, Sitbon O, Barst RJ, Manes A, Rubin LJ. Endothelin receptor antagonists in pulmonary arterial hypertension. J Am Coll Cardiol 2004;43:62S-67S.

74 Yoshibayashi M, Nishioka K, Nakao K, Saito Y, Matsumura M, Ueda T, et al. Plasma endothelin concentrations in patients with pulmonary hypertension associated with congenital heart defects. Evidence for increased production of endothelin in pulmonary circulation. Circulation 1991;84:2280-2285.
75 Ozerol IH, Pac FA, Ozerol E, Ege E, Yologlu S, Temel I, et al. Plasma endothelin-1, homocysteine and serum nitric oxide values in patients with left-to-right shunt. Indian Heart J 2004;56:653-657.
76 Rubin LJ, Badesch DB, Barst RJ, Galiè N, Black CM, Keogh A, et al. Bosentan therapy for pulmonary arterial hypertension. N Engl J Med 2002;346:896-903.
77 Maiya S, Hislop AA, Flynn Y, Haworth SG. Response to bosentan in children with pulmonary hypertension. Heart 2006; 92:664-670.
78 Gilbert N, Luther YC, Miera O, Nagdyman N, Ewert P, Berger F, et al. Initial experience with bosentan (Tracleer) as treatment for pulmonary arterial hypertension (PAH) due to congenital heart disease in infants and young children. Z Kardiol 2005;94: 570-574.
79 Rugolotto S, Errico G, Beghini R, Ilic S, Richelli C, Padovani EM. Weaning of epoprostenol in a small infant receiving concomitant bosentan for severe pulmonary arterial hypertension secondary to bronchopulmonary dysplasia. Minerva Pediatr 2006;58:491-494.
80 Votava-Smith JK, Perens GS, Alejos JC. Bosentan for increased pulmonary vascular resistance in a patient with single ventricle physiology and a bidirectional Glenn shunt. Pediatr Cardiol 2007;28:314-316.
81 Gatzoulis MA, Rogers P, Li W, Harries C, Cramer D, Ward S, et al. Safety and tolerability of bosentan in adults with Eisenmenger physiology. Int J Cardiol 2005;98:147-151.
82 Schulze-Neick I, Gilbert N, Ewert R, Witt C, Gruenig E, Enke B, et al. Adult patients with congenital heart disease and pulmonary arterial hypertension: first open prospective multicenter study of bosentan therapy. Am Heart J 2005;150:716.
83 Benza RL, Rayburn BK, Tallaj JA, Coffey CS, Pinderski LJ, Pamoukian SV, et al. Efficacy of bosentan in a small cohort of adult patients with pulmonary arterial hypertension related to congenital heart disease. Chest 2006;129:1009-1015.
84 Sitbon O, Beghetti M, Petit J, Iserin L, Humbert M, Gressin V, et al. Bosentan for the treatment of pulmonary arterial hypertension associated with congenital heart defects. Eur J Clin Invest 2006;36(Suppl 3):25-31.
85 Ibrahim R, Granton JT, Mehta S. An open-label, multicentre pilot study of bosentan in pulmonary arterial hypertension related to congenital heart disease. Can Respir J 2006;13: 415-420.
86 D'Alto M, Vizza CD, Romeo E, Badagliacca R, Santoro G, Poscia R, et al. Long term effects of bosentan treatment in adult patients with pulmonary arterial hypertension related to congenital heart disease (Eisenmenger physiology): safety, tolerability, clinical, and haemodynamic effect. Heart 2007;93:621-625.
87 Diller GP, Dimopoulos K, Kaya MG, Harries C, Uebing A, Li W, et al. Long-term safety, tolerability and efficacy of bosentan in adults with pulmonary arterial hypertension associated with congenital heart disease. Heart 2007;93:974-976.
88 Kotlyar E, Sy R, Keogh AM, Kermeen F, Macdonald PS, Hayward CS, et al. Bosentan for the treatment of pulmonary arterial hypertension associated with congenital cardiac disease. Cardiol Young 2006;16:268-274.
89 Durongpisitkul K, Jakrapanichakul D, Sompradikul S. A retrospective study of bosentan in pulmonary arterial hypertension associated with congenital heart disease. J Med Assoc Thai 2008;91:196-202.
90 van Loon RL, Hoendermis ES, Duffels MG, Vonk-Noordegraaf A, Mulder BJ, Hillege HL, et al. Long-term effect of bosentan in adults versus children with pulmonary arterial hypertension associated with systemic-to-pulmonary shunt: does the beneficial effect persist? Am Heart J 2007;154:776-782.
91 Apostolopoulou SC, Manginas A, Cokkinos DV, Rammos S. Long-term oral bosentan treatment in patients with pulmonary arterial hypertension related to congenital heart disease: a 2-year study. Heart 2007;93:350-354.
92 Galiè N, Beghetti M, Gatzoulis MA, Granton J, Berger RM, Lauer A, et al. Bosentan therapy in patients with Eisenmenger syndrome: a multicenter, double-blind, randomized, placebo-controlled study. Circulation 2006;114:48-54.
93 Galiè N, Rubin LJ, Hoeper MM, Jansa P, Al-Hiti H, Meyer GM, et al. Treatment of patients with mildly symptomatic pulmonary arterial hypertension with bosentan (EARLY) study: a double-blind, randomised, controlled trial. Lancet 2008;371:2093-2100.
94 Barst RJ, Ivy D, Dingemanse J, Widlitz A, Schmitt K, Doran A, et al. Pharmacokinetics, safety, and efficacy of bosentan in pediatric patients with pulmonary arterial hypertension. Clin Pharmacol Ther 2003;73:372-382.
95 Barst RJ, Langleben D, Frost A, Horn EM, Oudiz R, Shapiro S, et al. Sitaxsentan therapy for pulmonary arterial hypertension. Am J Respir Crit Care Med 2004;169:441-447.
96 Barst RJ, Langleben D, Badesch D, Frost A, Lawrence EC, Shapiro S, et al. Treatment of pulmonary arterial hypertension with the selective endothelin-A receptor antagonist sitaxsentan. J Am Coll Cardiol 2006;47:2049-2056.
97 Langleben D, Hirsch AM, Shalit E, Lesenko L, Barst RJ. Sustained symptomatic, functional, and hemodynamic benefit with the selective endothelin-A receptor antagonist, sitaxsentan, in patients with pulmonary arterial hypertension: a 1-year follow-up study. Chest 2004;126:1377-1381.
98 Benza RL, Mehta S, Keogh A, Lawrence EC, Oudiz RJ, Barst RJ. Sitaxsentan treatment for patients with pulmonary arterial hypertension discontinuing bosentan. J Heart Lung Transplant 2007;26:63-69.
99 Galiè N, Badesch D, Oudiz R, Simonneau G, McGoon MD, Keogh AM, et al. Ambrisentan therapy for pulmonary arterial hypertension. J Am Coll Cardiol 2005;46:529-535.
100 Galiè N, Ghofrani HA, Torbicki A, Barst RJ, Rubin LJ, Badesch D, et al. Sildenafil citrate therapy for pulmonary arterial hypertension. N Engl J Med 2005;353:2148-2157.
101 Kothari SS, Duggal B. Chronic oral sildenafil therapy in severe pulmonary artery hypertension. Indian Heart J 2002;54: 404-409.
102 Raposo-Sonnenfeld I, Otero-González I, Blanco-Aparicio M, Ferrer-Barba Á, Medrano-López C. Treatment with sildenafil, bosentan, or both in children and young people with idiopathic pulmonary arterial hypertension and Eisenmenger's syndrome. Rev Esp Cardiol 2007;60:366-372.
103 Giardini A, Balducci A, Specchia S, Gargiulo G, Bonvicini M, Picchio FM. Effect of sildenafil on haemodynamic response to exercise and exercise capacity in Fontan patients. Eur Heart J 2008;29:1681-1687.
104 Peiravian F, Amirghofran AA, Borzouee M, Ajami GH, Sabri MR, Kolaee S. Oral sildenafil to control pulmonary hypertension after congenital heart surgery. Asian Cardiovasc

Thorac Ann 2007;15:113-117.
105 Raja SG, Danton MD, MacArthur KJ, Pollock JC. Effects of escalating doses of sildenafil on hemodynamics and gas exchange in children with pulmonary hypertension and congenital cardiac defects. J Cardiothorac Vasc Anesth 2007;21: 203-207.
106 Kovacikova L, Zahorec M, Nosal M. Sildenafil as a pulmonary vasodilator after repair of congenital heart disease. Bratisl Lek Listy 2007;108:453-454.
107 Namachivayam P, Theilen U, Butt WW, Cooper SM, Penny DJ, Shekerdemian LS. Sildenafil prevents rebound pulmonary hypertension after withdrawal of nitric oxide in children. Am J Respir Crit Care Med 2006;174:1042-1047.
108 Schulze-Neick I, Hartenstein P, Li J, Stiller B, Nagdyman N, Hübler M, et al. Intravenous sildenafil is a potent pulmonary vasodilator in children with congenital heart disease. Circulation 2003;108(Suppl 1):II167-173.
109 Lammers AE, Haworth SG, Pierce CM. Intravenous sildenafil as an effective treatment of pulmonary hypertensive crises during acute intestinal malabsorption. Cardiol Young 2006;16: 84-86.
110 Karatza AA, Bush A, Magee AG. Safety and efficacy of Sildenafil therapy in children with pulmonary hypertension. Int J Cardiol 2005;100:267-273.
111 Noori S, Friedlich P, Wong P, Garingo A, Seri I. Cardiovascular effects of sildenafil in neonates and infants with congenital diaphragmatic hernia and pulmonary hypertension. Neonatology 2007;91:92-100.
112 Murad F. Nitric oxide and cyclic GMP in cell signaling and drug development. N Engl J Med 2006;355:2003-2011.
113 Waldman JD, Lamberti JJ, Mathewson JW, Kirkpatrick SE, Turner SW, George L, et al. Congenital heart disease and pulmonary artery hypertension. I. Pulmonary vasoreactivity to 15% oxygen before and after surgery. J Am Coll Cardiol 1983;2:1158-1164.
114 Kotake F, Kobayashi J, Sonoda M, Komoda T. Nitric oxide-related compounds in patients with congenital heart defects and pulmonary hypertension. Pediatr Int 2000;42:249-254.
115 Kiettisanpipop P, Lertsapcharorn P, Chotivittayatarakorn P, Poovorawan Y. Plasma levels of nitric oxide in children with congenital heart disease and increased pulmonary blood flow. J Med Assoc Thai 2007;90:2053-2057.
116 Journois D, Pouard P, Mauriat P, Malhère T, Vouhé P, Safran D. Inhaled nitric oxide as a therapy for pulmonary hypertension after operations for congenital heart defects. J Thorac Cardiovas Surg 1994;107:1129-1135.
117 Beghetti M, Habre W, Friedli B, Berner M. Continuous low dose inhaled nitric oxide for treatment of severe pulmonary hypertension after cardiac surgery in paediatric patients. Br Heart J 1995;73:65-68.
118 Goldman AP, Delius RE, Deanfield JE, Macrae DJ. Nitric oxide is superior to prostacyclin for pulmonary hypertension after cardiac operations. Ann Thorac Surg 1995;60:300-305.
119 Shimpo H, Mitani Y, Tanaka J, Mizumoto T, Onoda K, Tani K, et al. Inhaled low-dose nitric oxide for postoperative care in patients with congenital heart defects. Artif Organs 1997; 21:10-13.
120 Russell IA, Zwass MS, Fineman JR, Balea M, Rouine-Rapp K, Brook M, et al. The effects of inhaled nitric oxide on postoperative pulmonary hypertension in infants and children undergoing surgical repair of congenital heart disease. Anesth Analg 1998;87:46-51.
121 Murthy KS, Rao SG, Prakash KS, Robert C, Dhinakar S, Cherian KM. Role of inhaled nitric oxide as a selective pulmonary vasodilator in pediatric cardiac surgical practice. Indian J Pediatr 1999;66:357-361.
122 Göthberg S, Edberg KE. Inhaled nitric oxide to newborns and infants after congenital heart surgery on cardiopulmonary bypass. A dose-response study. Scan Cardiovasc J 2000;34: 154-158.
123 Day RW, Hawkins JA, McGough EC, Crezeé KL, Orsmond GS. Randomized controlled study of inhaled nitric oxide after operation for congenital heart disease. Ann Thorac Surg 2000;69:1907-1912.
124 Sharma R, Raizada N, Choudhary SK, Bhan A, Kumar P, Juneja R, et al. Does inhaled nitric oxide improve survival in operated congenital disease with severe pulmonary hypertension? Indian Heart J 2001;53:48-55.
125 Pérez-Peñate G, Cabrera Navarro P, Ponce González M, Górriz Gómez E, Pulido Duque J, García Quintana A, et al. Long-term inhaled nitric oxide plus dipyridamole for pulmonary arterial hypertension. Respiration 2005;72:419-422.
126 Goyal P, Kiran U, Chauhan S, Juneja R, Choudhary M. Efficacy of nitroglycerin inhalation in reducing pulmonary arterial hypertension in children with congenital heart disease. Br J Anaesth 2006;97:208-214.
127 Omar HA, Gong F, Sun MY, Einzig S. Nebulized nitroglycerin in children with pulmonary hypertension secondary to congenital heart disease. W V Med J 1999;95:74-75.
128 Levine DJ. Diagnosis and management of pulmonary arterial hypertension: implications for respiratory care. Respir Care 2006;51:368-381.
129 Rosenzweig EB, Ivy DD, Widlitz A, Doran A, Claussen LR, Yung D, et al. Effects of long-term bosentan in children with pulmonary arterial hypertension. J Am Coll Cardiol 2005;46:697-704.
130 Ghofrani HA, Rose F, Schermuly RT, Olschewski H, Wiedemann R, Kreckel A, et al. Oral sildenafil as long-term adjunct therapy to inhaled iloprost in severe pulmonary arterial hypertension. J Am Coll Cardiol 2003;42:158-164.
131 Lunze K, Gilbert N, Mebus S, Miera O, Fehske W, Uhlemann F, et al. First experience with an oral combination therapy using bosentan and sildenafil for pulmonary arterial hypertension. Eur J Clin Invest 2006;36(Suppl 3):32-38.
132 Channick R, Williamson TL. Diagnosis and treatment of pulmonary arterial hypertension. Cardiol Clin 2004;22:441-452.
133 Robbins IM, Kawut SM, Yung D, Reilly MP, Lloyd W, Cunningham G, et al. A study of aspirin and clopidogrel in idiopathic pulmonary arterial hypertension. Eur Respir J 2006; 27:578-584.
134 Barr FE, Beverley H, VanHook K, Cermak E, Christian K, Drinkwater D, et al. Effect of cardiopulmonary bypass on urea cycle intermediates and nitric oxide levels after congenital heart surgery. J Pediatr 2003;142:26-30.
135 Smith HA, Canter JA, Christian KG, Drinkwater DC, Scholl FG, Christman BW, et al. Nitric oxide precursors and congenital heart surgery: a randomized controlled trial of oral citrulline. J Thorac Cardiovasc Surg 2006;132:58-65.
136 Barr FE, Tirona RG, Taylor MB, Rice G, Arnold J, Cunningham G, et al. Pharmacokinetics and safety of intravenously administered citrulline in children undergoing congenital heart surgery: potential therapy for postoperative pulmonary hypertension. J Thorac Cardiovasc Surg 2007;134:319-326.
137 Klepetko W, Mayer E, Sandoval J, Trulock EP, Vachiery JL, Dartevelle P, et al. Interventional and surgical modalities of

treatment for pulmonary arterial hypertension. J Am Coll Cardiol 2004;43:73S-80S.
138 Landzberg MJ. Emerging therapy of congenital heart disease associated with pulmonary hypertension. Adv Pulmonary Hypertens 2007;6:136-141.
139 Khan IU, Ahmed I, Mufti WA, Rashid A, Khan AA, Ahmed SA, et al. Ventricular septal defect in infants and children with increased pulmonary vascular resistance and pulmonary hypertension—surgical management: leaving an atrial level communication. J Ayub Med Coll Abbottabad 2006;18:21-25.
140 Larios R, Fitch EA, Blanco G, Bailey CP. The use of an artificial foraminal valve prosthesis in the closure of interatrial and interventricular septal defect. Dis Chest 1959;36:631-641.
141 Novick WM, Gurbuz AT, Watson DC, Lazorishinets VV, Perepeka AN, Malcic I, et al. Double patch closure of ventricular septal defect with increased pulmonary vascular resistance. Ann Thorac Surg 1998;66:1533-1538.
142 Novick WM, Sandoval N, Lazorhysynets VV, Castillo V, Baskevitch A, Mo X, et al. Flap valve double patch closure of ventricular septal defects in children with increased pulmonary vascular resistance. Ann Thorac Surg 2005;79:21-28.
143 Afrasiabi A, Samadi M, Montazergaem H. Valved patch for ventricular septal defect with pulmonary arterial hypertension. Asian Cardiovasc Thorac Ann 2006;14:501-504.
144 Zhang B, Wu S, Liang J, Zhang G, Jiang G, Zhou M, et al. Unidirectional monovalve homologous aortic patch for repair of ventricular septal defect with pulmonary hypertension. Ann Thorac Surg 2007;83:2176-2181.
145 Waddell TK, Bennett L, Kennedy R, Todd TR, Keshavjee SH. Heart-lung or lung transplantation for Eisenmenger syndrome. J Heart Lung Transplant 2002;21:731-737.
146 Choong CK, Sweet SC, Guthrie TJ, Mendeloff EN, Haddad FJ, Schuler P, et al. Repair of congenital heart lesions combined with lung transplantation for the treatment of severe pulmonary hypertension: a 13-year experience. J Thorac Cardiovasc Surg 2005;129:661-669.
147 Diller GP, Dimopoulos K, Broberg CS, Kaya MG, Naghotra US, Uebing A, et al. Presentation, survival prospects, and predictors of death in Eisenmenger syndrome: a combined retrospective and case-control study. Eur Heart J 2006;27:1737-1742.
148 Radley-Smith R, Aurora P. Transplantation as a treatment for end-stage pulmonary hypertension in childhood. Paediatr Respir Rev 2006;7:117-122.

Received October 6, 2008
Accepted after revision April 8, 2009